

# US of the L-spine:

muscles, facet joints, the medial branch of spinal nerves, sacrum and SI joints

台大醫院麻醉部疼痛科

周韋翰醫師

# Ultrasound is better?

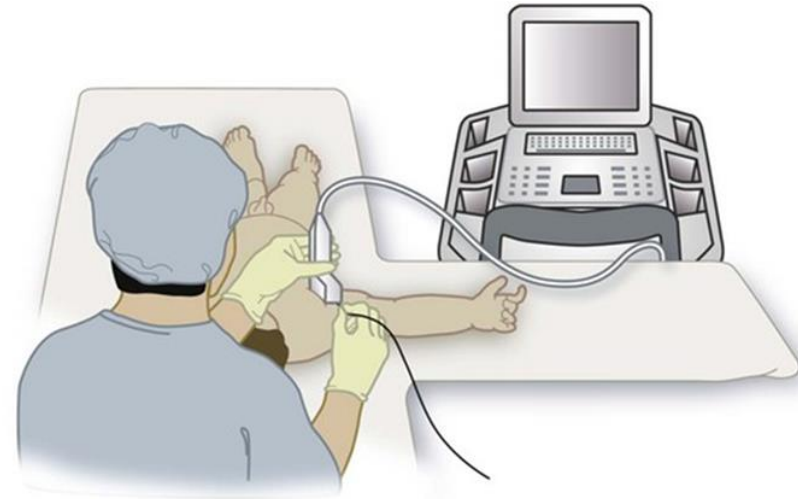
- More affordable and **transferrable**
- Enables the detection of **blood vessels**
- **Reduces radiation** exposure
- More **effective than CT-/fluoroscopy-guided** techniques for pain relief and improvement of disability?



1. Paloma Morillas-Sendin, *et al.* Basic considerations before injections and scanning techniques. *Techniques in Regional Anesthesia and Pain Management*. 2013; 17(3): 53-63
2. Tao Wu, *et al.* Effectiveness of Ultrasound-Guided Versus Fluoroscopy or Computed Tomography Scanning Guidance in Lumbar Facet Joint Injections in Adults With Facet Joint Syndrome: A Meta-Analysis of Controlled Trials. *Arch Phys Med Rehabil*. 2016 Sep; 97(9): 1558-1563
3. Ye L, *et al.* Ultrasound-guided versus low dose computed tomography scanning guidance for lumbar facet joint injections: same accuracy and efficiency. *BMC Anesthesiol*. 2018 Nov 7;18(1):160

# Practice tips

- US machine on the opposite side
- The monitor in the line of sight
- May take a seat, rest your arm
- **No** arching torso
- **No** turn head > 45 degree
- **No** cross hands
- Novices: needle on the dominant hand



Paloma Morillas-Sendin, *et al.* Basic considerations before injections and scanning techniques. *Techniques in Regional Anesthesia and Pain Management*. 2013; 17(3): 53-63

# Outline

## Thoracic spine

- Transverse view
- Sagittal view

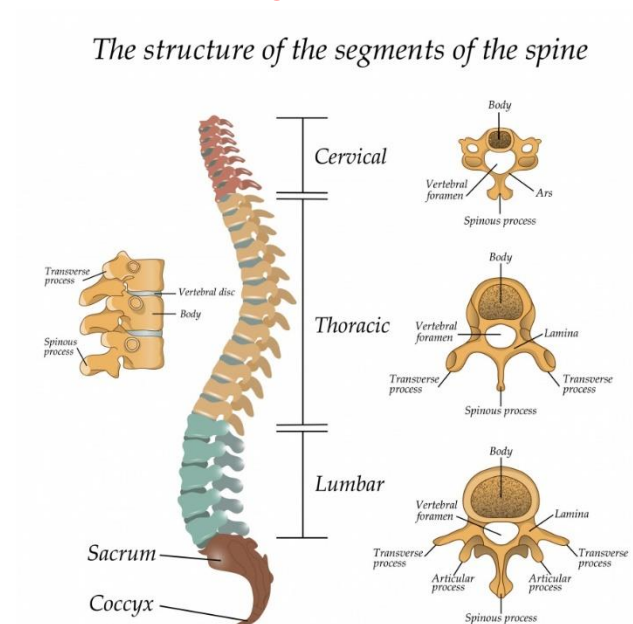
## Lumbar spine

- Low back muscles
- Facet joint and medial branch nerves

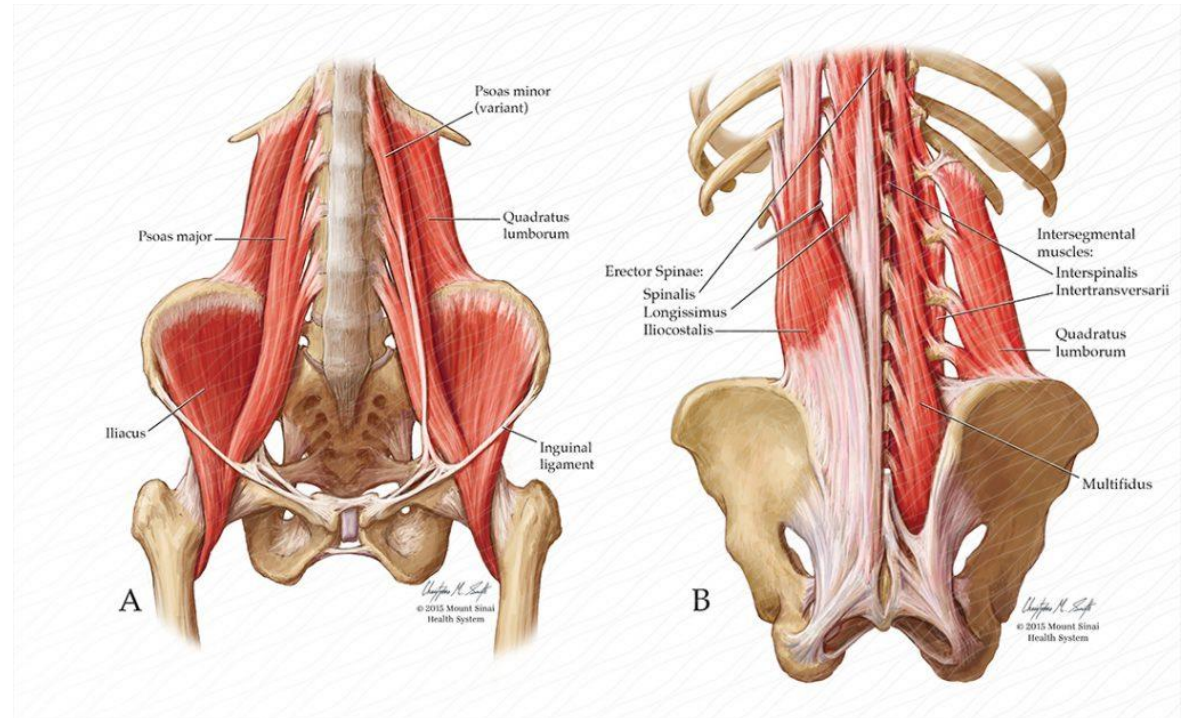
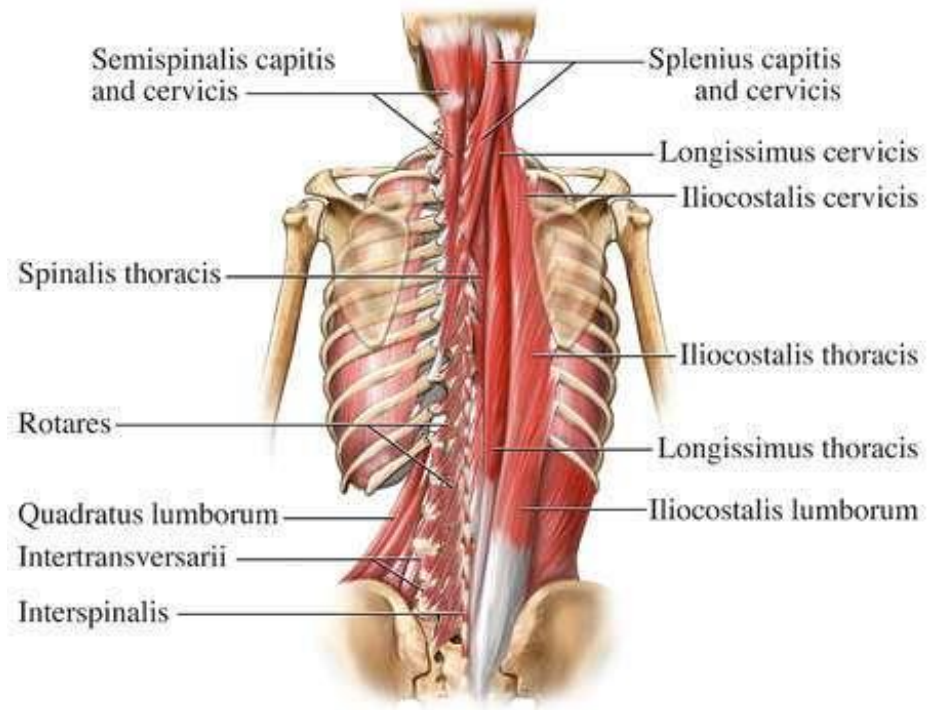
## Sacral region

- Sacral foramen
- Sacroiliac joint
- Caudal injection

- ◆ Anatomy
- ◆ Scanning techniques

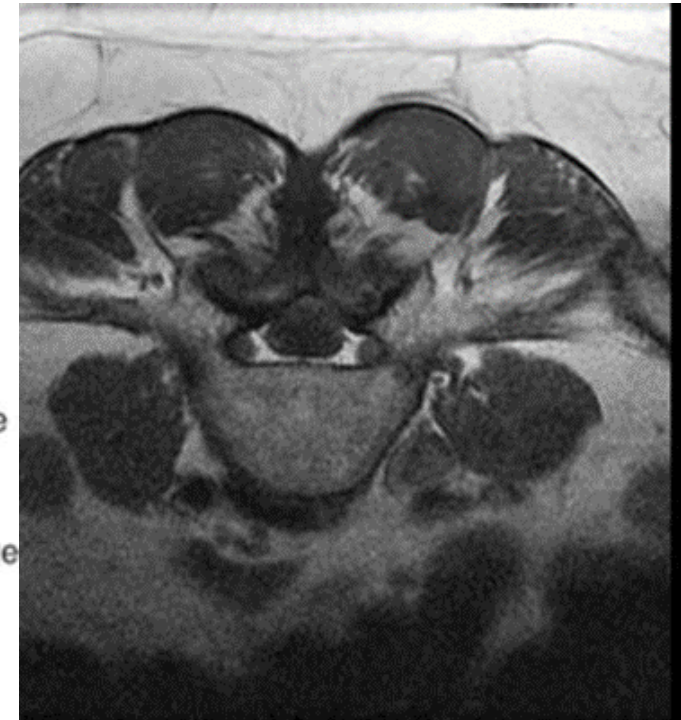
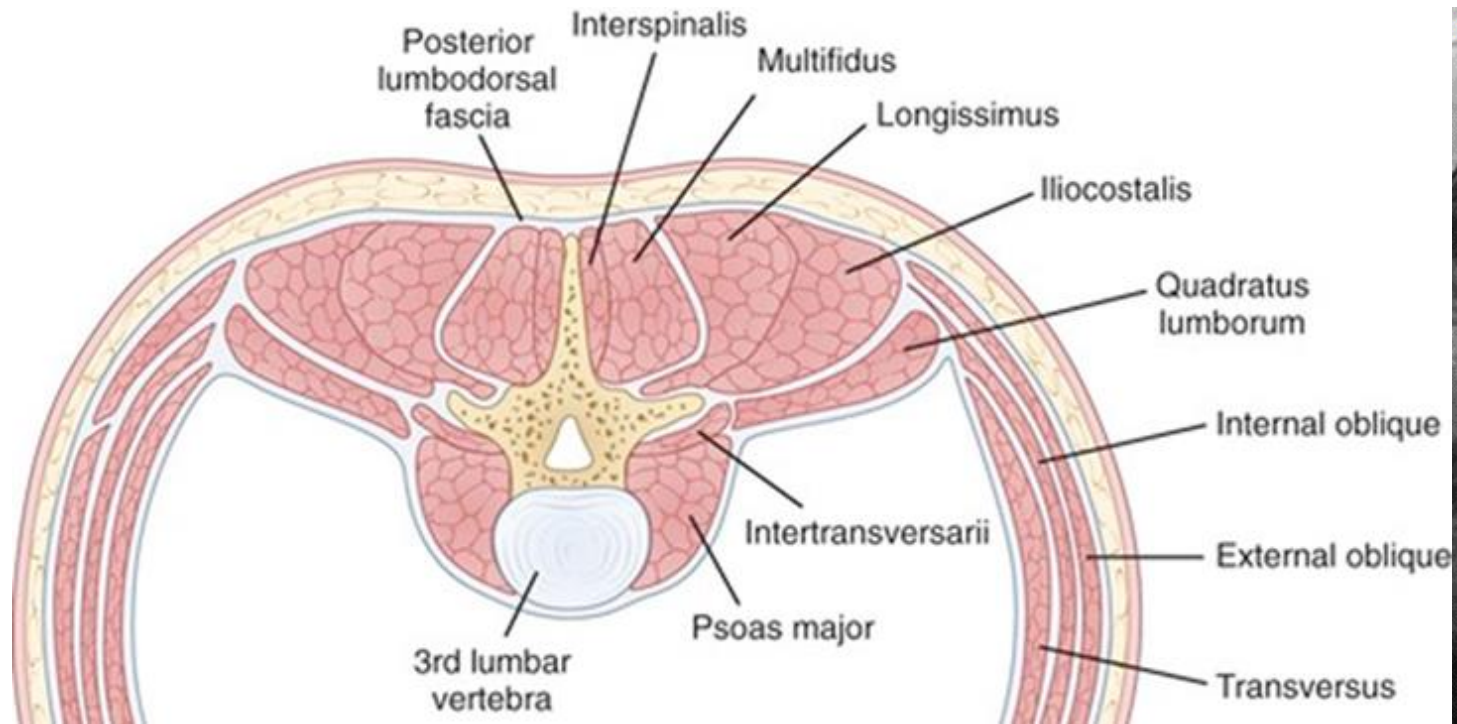


# Low back muscles

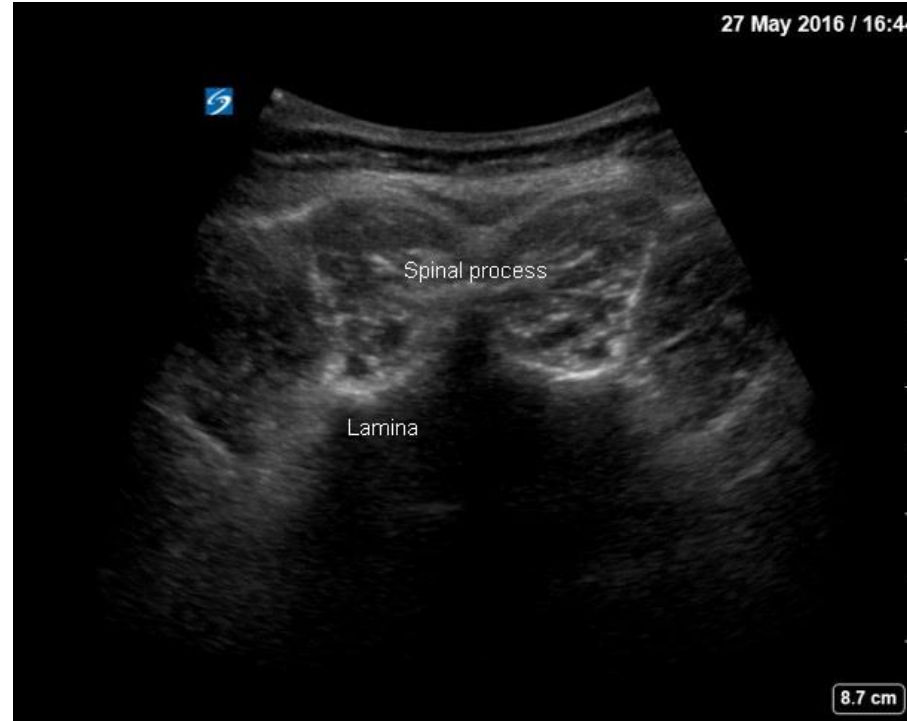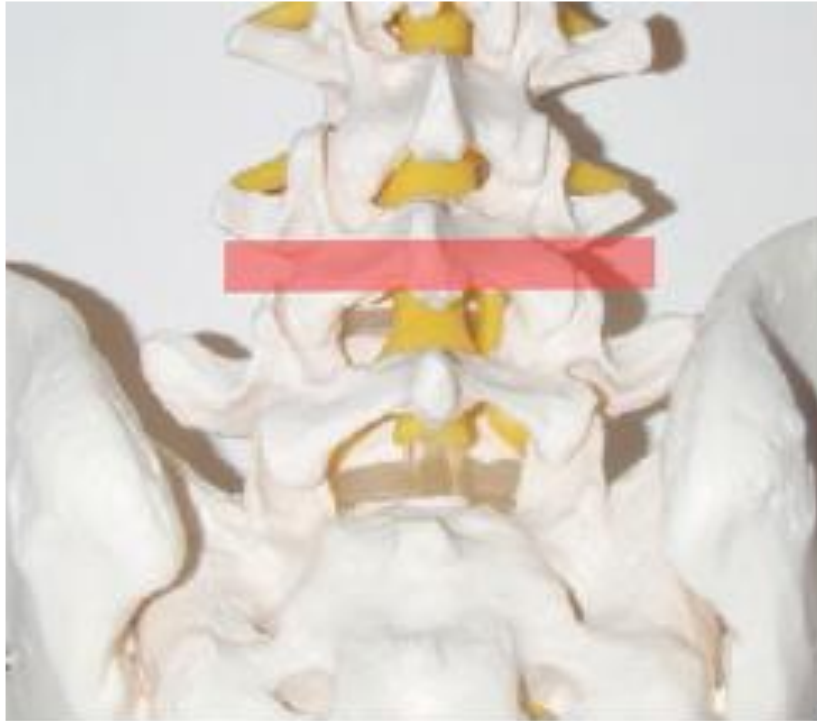




# Low back muscles

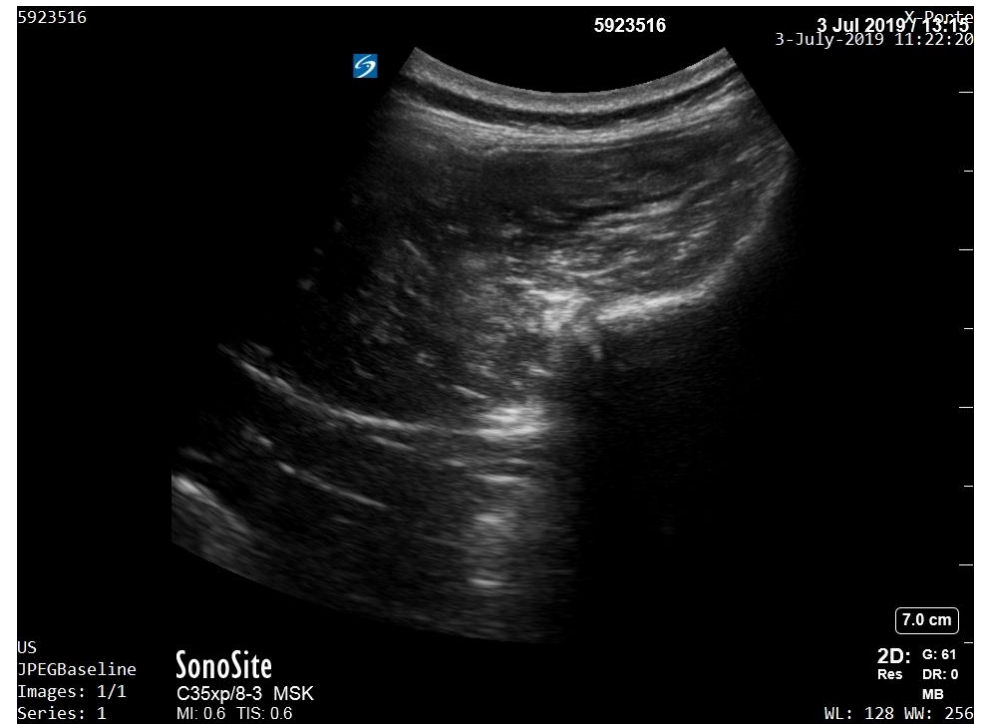
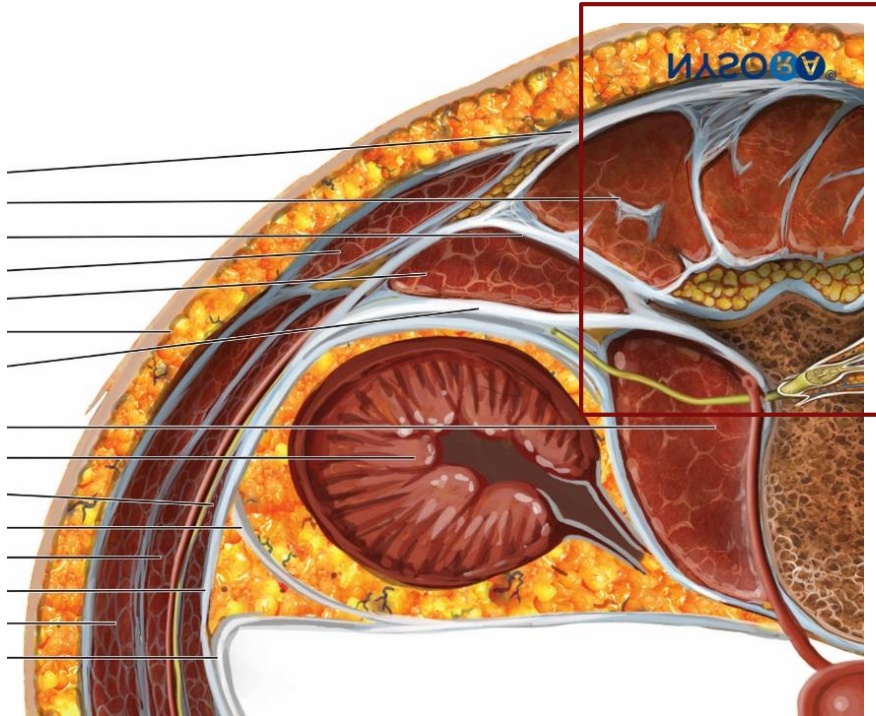


# Low back muscles



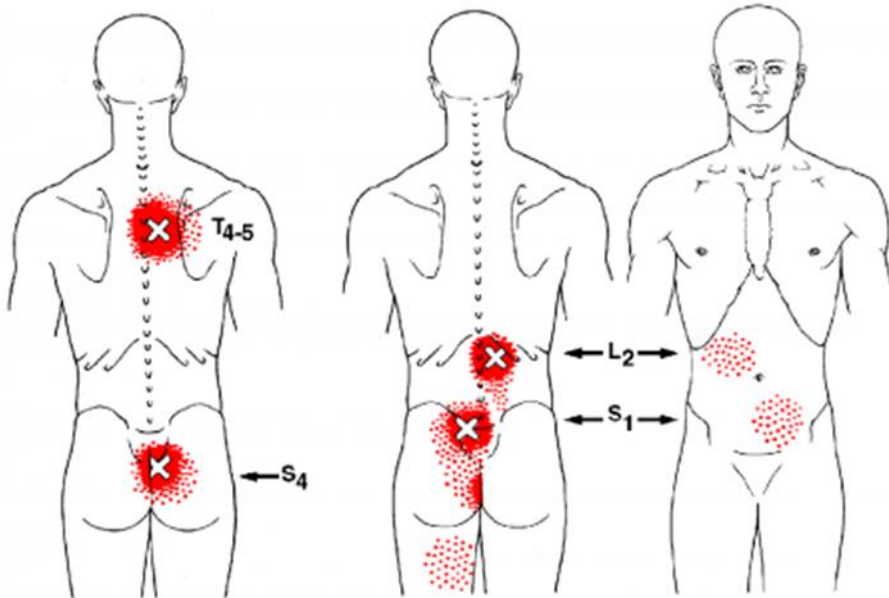
Samer N. Narouze: Atlas of Ultrasound-Guided Procedures in Interventional Pain Management, 1<sup>st</sup> edition. Springer, 2010, pp 151-3

# Low back muscles

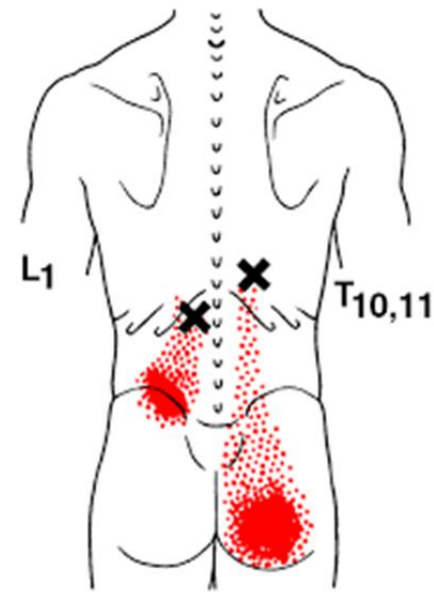




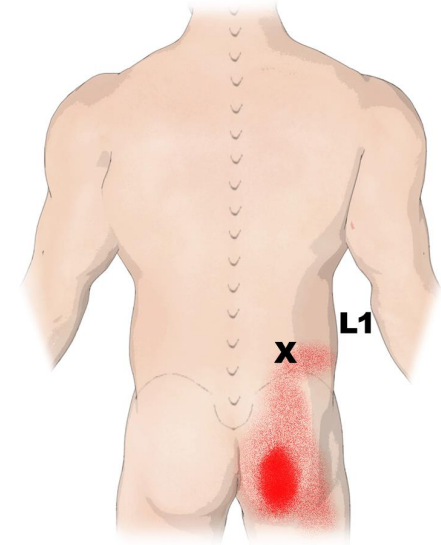
# Trigger point of lumbar spine muscles



Multifidus muscle

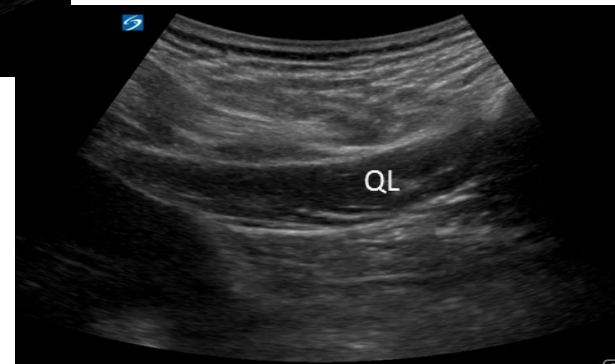
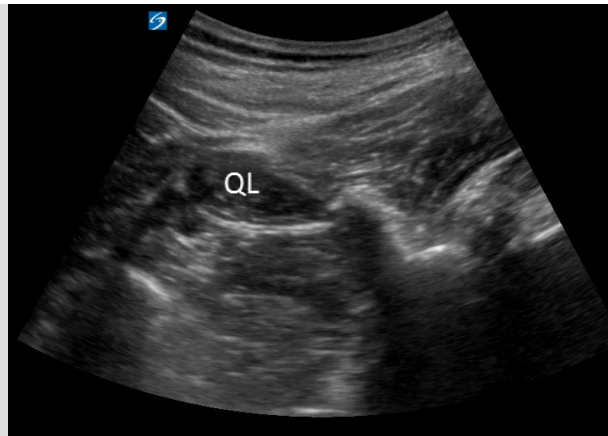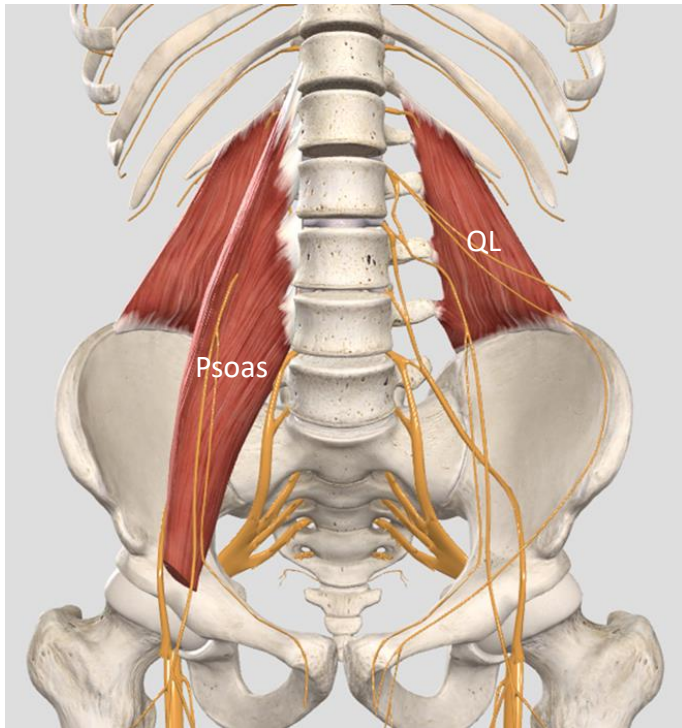


Longissimus

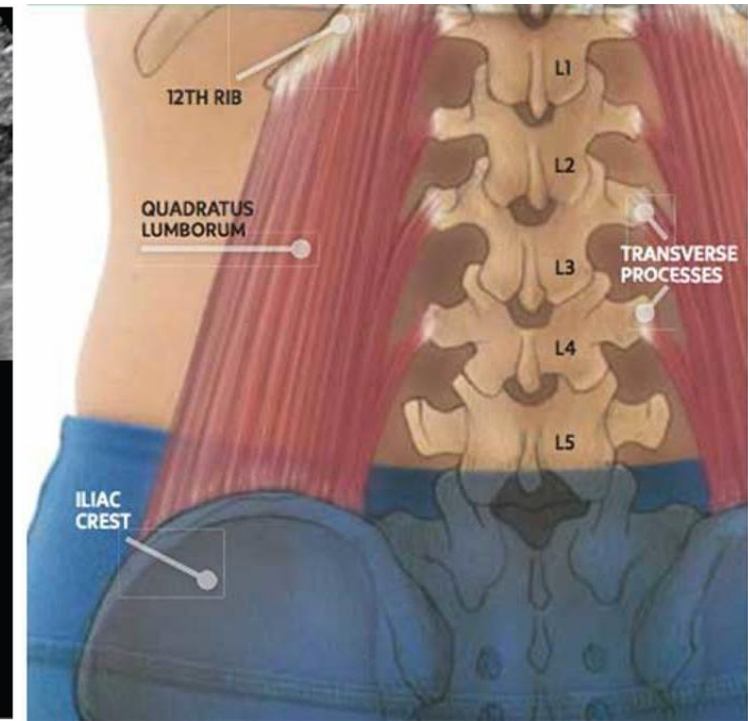
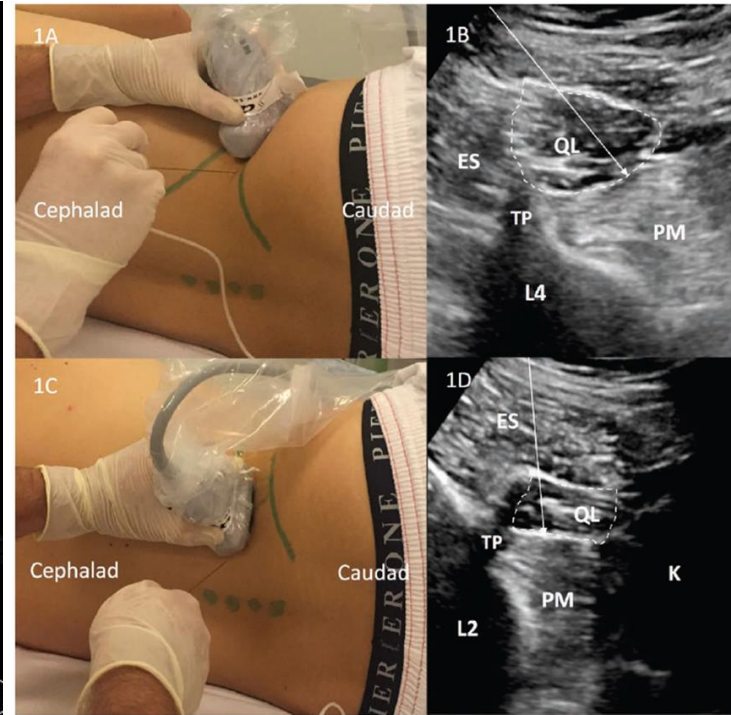
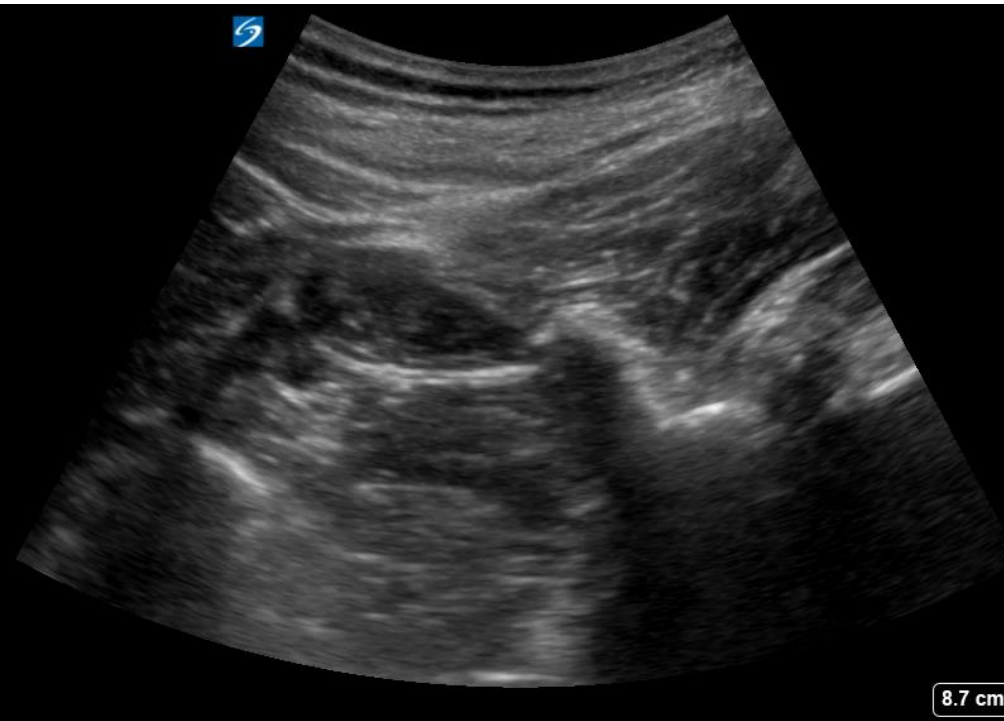


Iliocostalis-lumborum

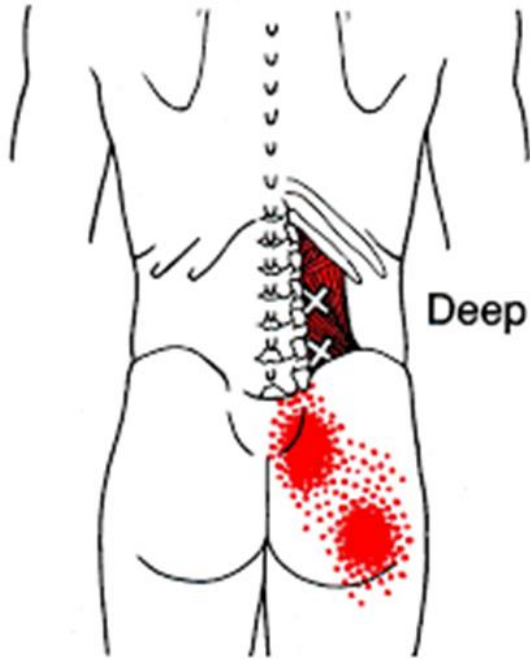
# Quadratus Lumborum & Psoas muscles



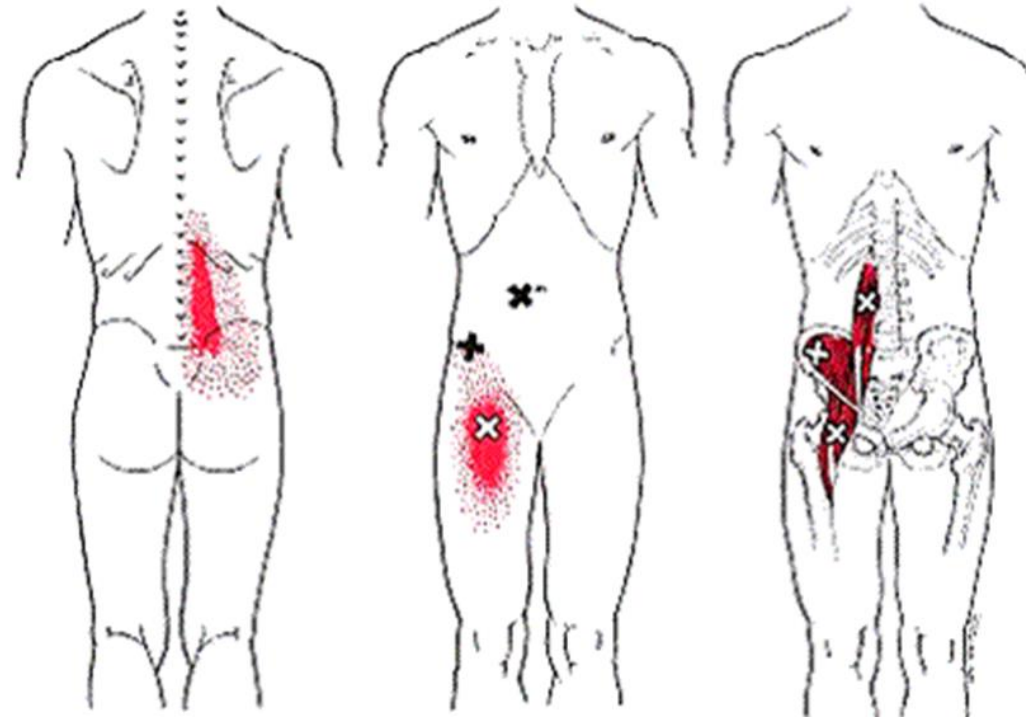
# Quadratus Lumborum & Psoas muscles



# Trigger point of lumbar spine muscles



Quadratus lumborum

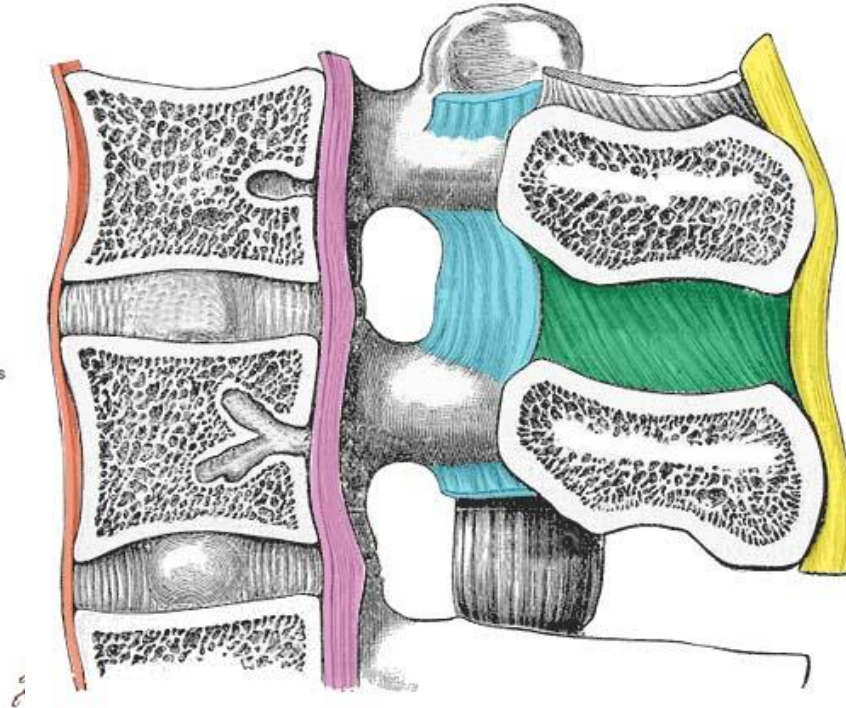
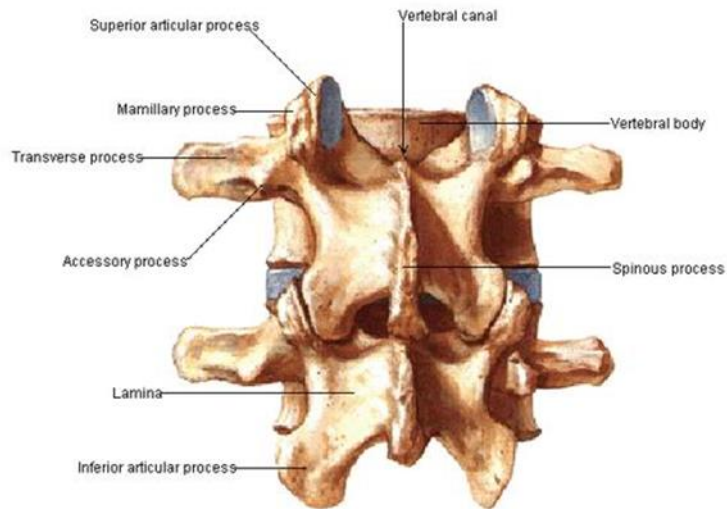


Psoas muscle

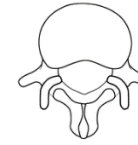


# Facet joint and the medial branch nerve- **Anatomy**

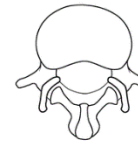
**Lumbar Vertebrae [L3-L4] - Assembled**  
Posterior View



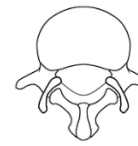
L1-2



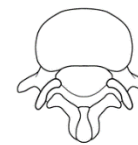
L2-3



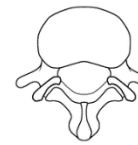
L3-4



L4-5

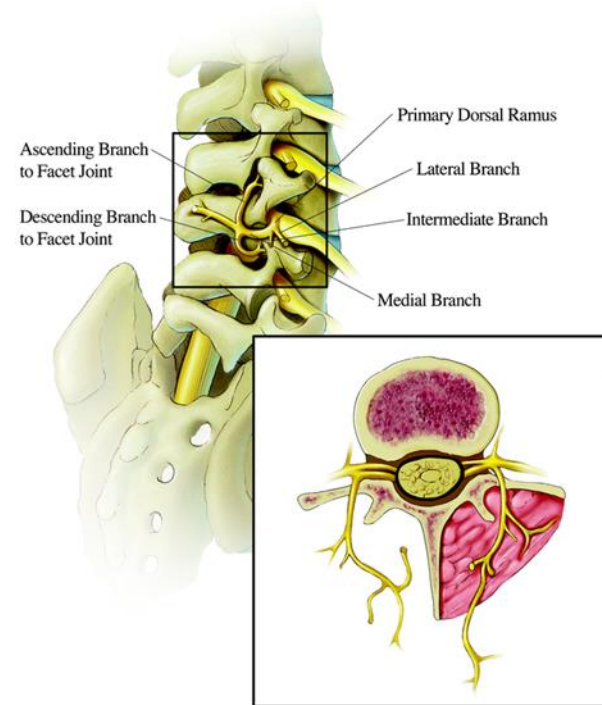
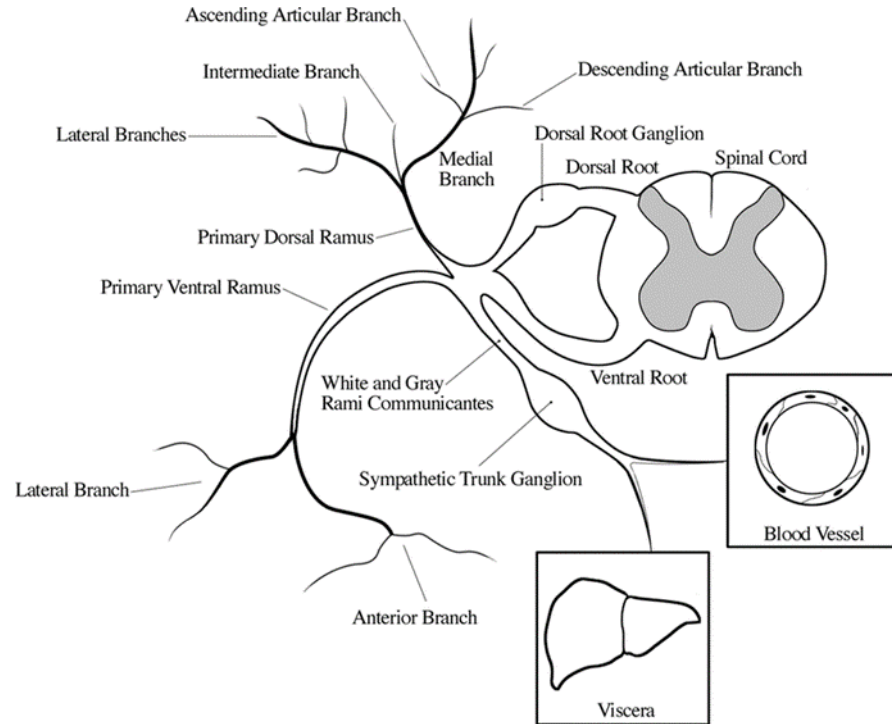


L5-S1





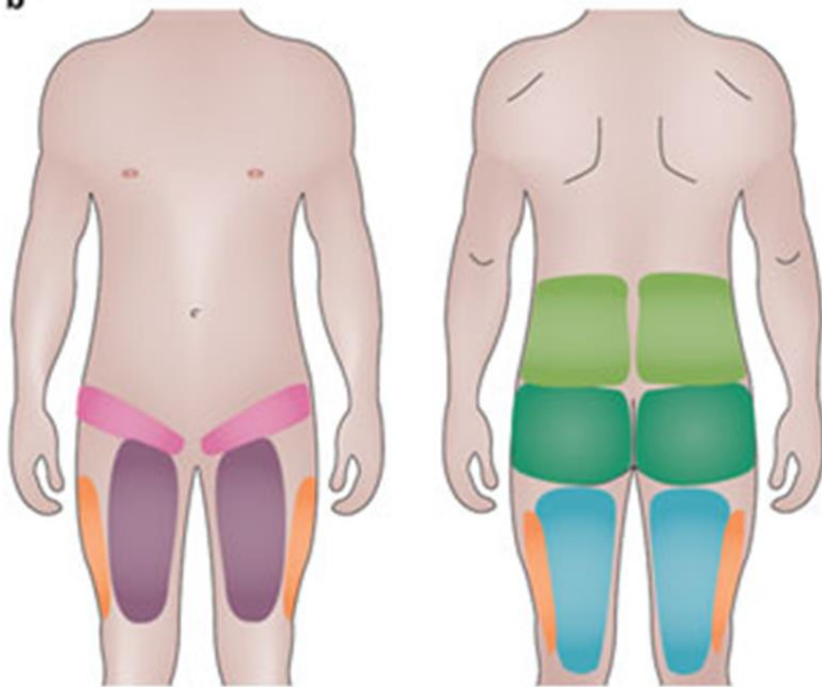
# Segmental spinal innervation



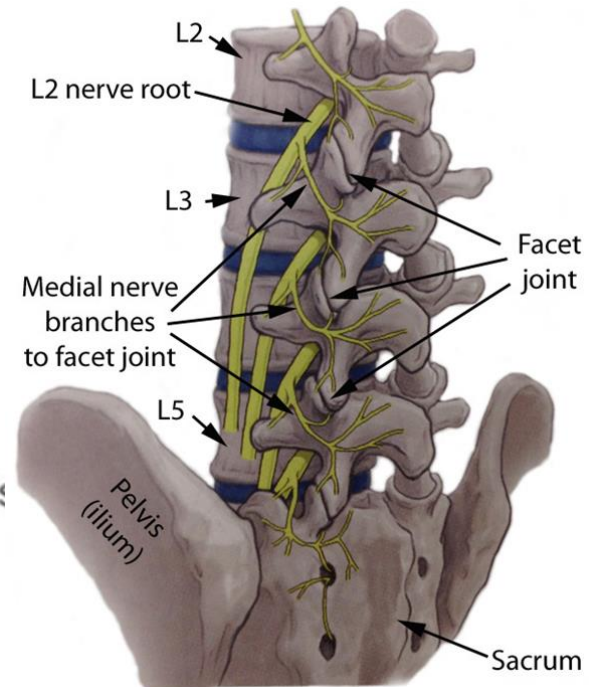
Cohen SP, Raja SN. Pathogenesis, diagnosis, and treatment of lumbar zygapophysial (facet) joint pain. *Anesthesiology*. 2007 Mar;106(3):591-614.

# Facet joint and the medial branch nerve- Anatomy

b



- Lumbar (L1-L5)
- Lower lumbar/gluteal (L2-S1)
- Posterior thigh (L3-S1)
- Lateral thigh (L2-S1)
- Anterior thigh (L3-S1)
- Groin (L3-S1)



# Facet joint and the medial branch nerve

**Table 1. Motions Associated with the Largest Intervertebral Angulation and Strain for the Lumbar Facet Joints**

Facet Joint Level	Movement Associated with Maximal IVA	Largest Strain
L1–L2	Right bending	Right bending
L2–L3	Left bending	Right bending
L3–L4	Right bending	Right bending
L4–L5	Forward flexion	Forward flexion
L5–S1	Extension	Forward flexion

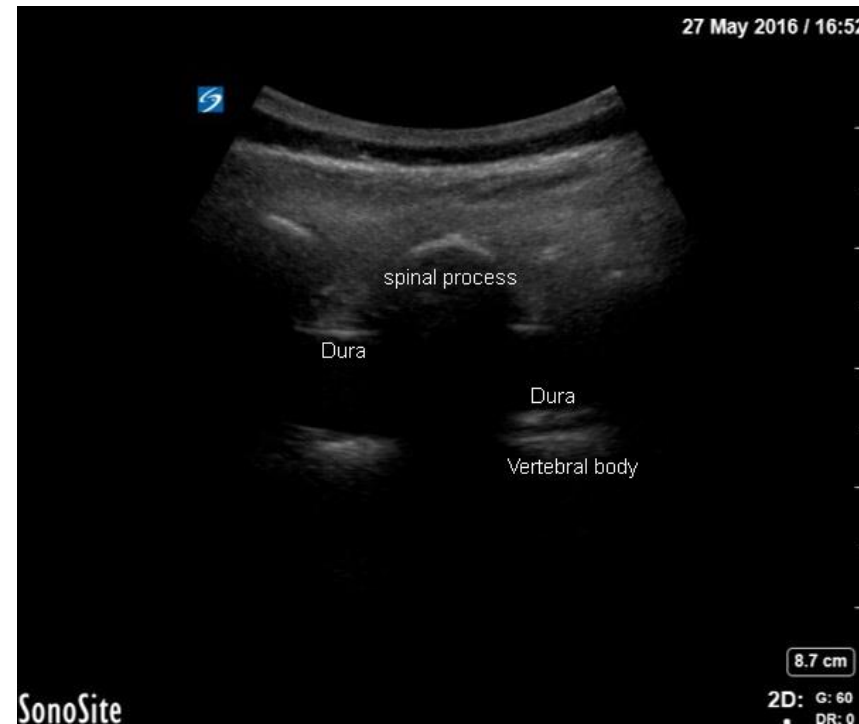
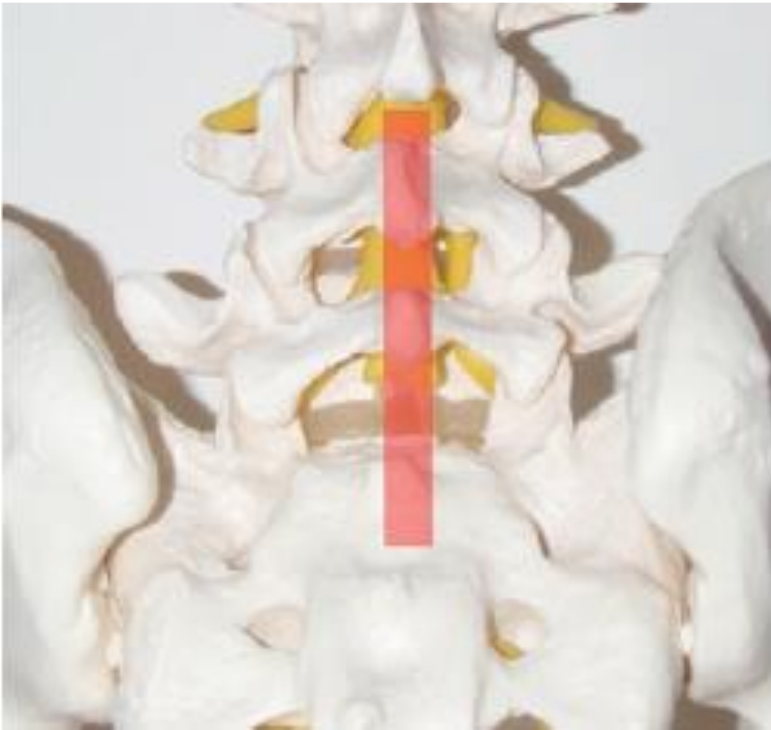
IVA = intervertebral angle.

Modified from Ianuzzi *et al.*<sup>62</sup>

Cohen SP, Raja SN. Pathogenesis, diagnosis, and treatment of lumbar zygapophysial (facet) joint pain. *Anesthesiology*. 2007 Mar;106(3):591-614.

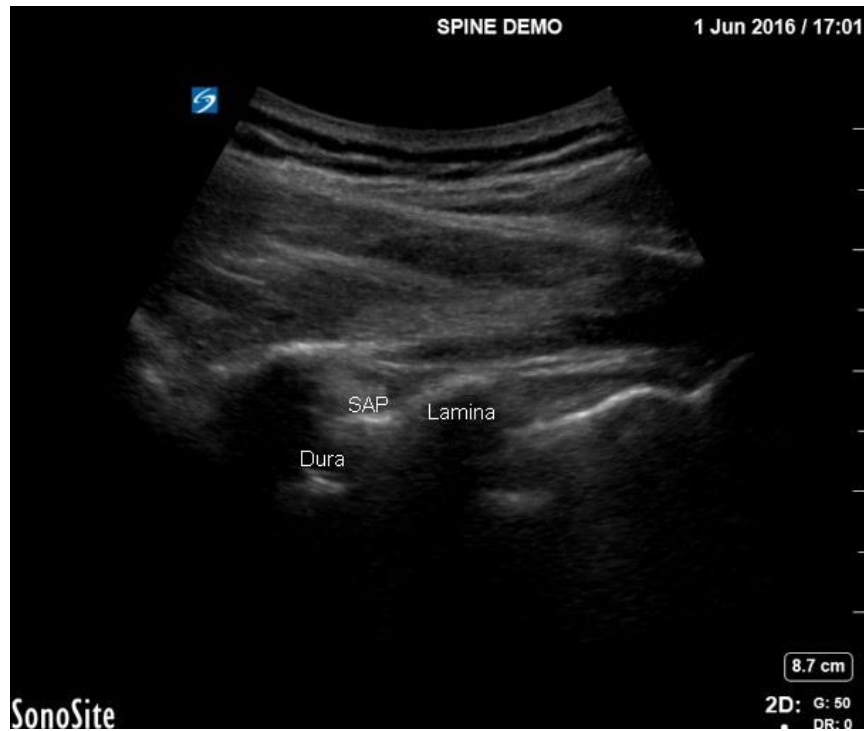
# Facet joints and the medial branch nerves

## Scanning technique-從中到外



# Facet joints and the medial branch nerves

## Scanning technique-從中到外



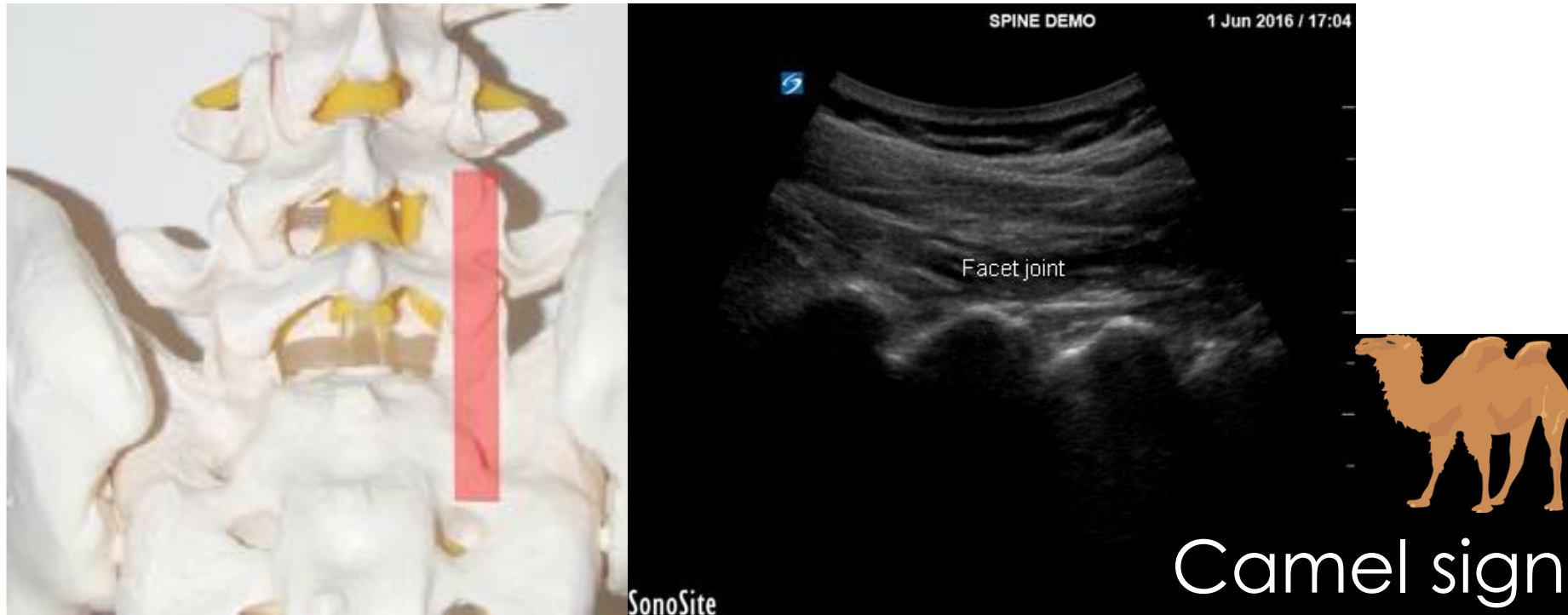## Horse head sign





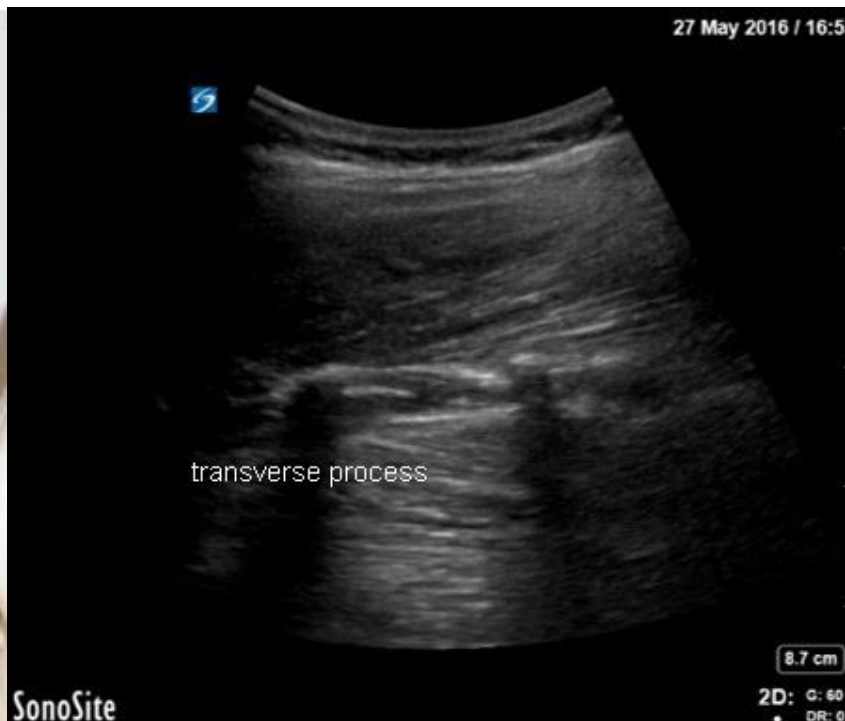
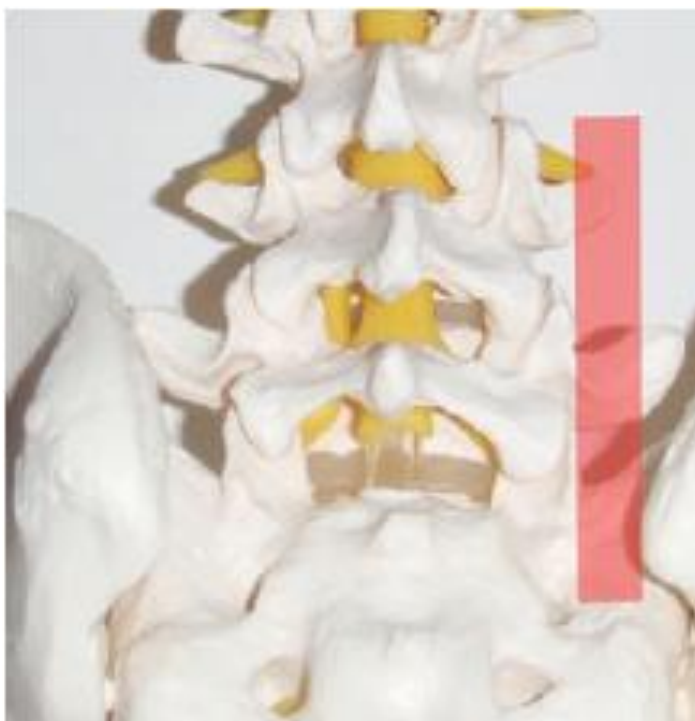# Facet joints and the medial branch nerves

## Scanning technique- 從中到外



# Facet joints and the medial branch nerves

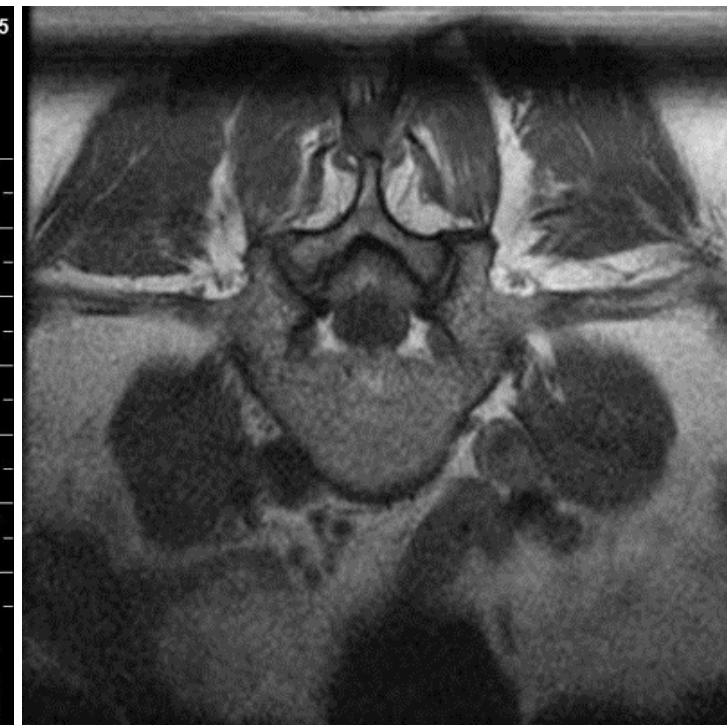
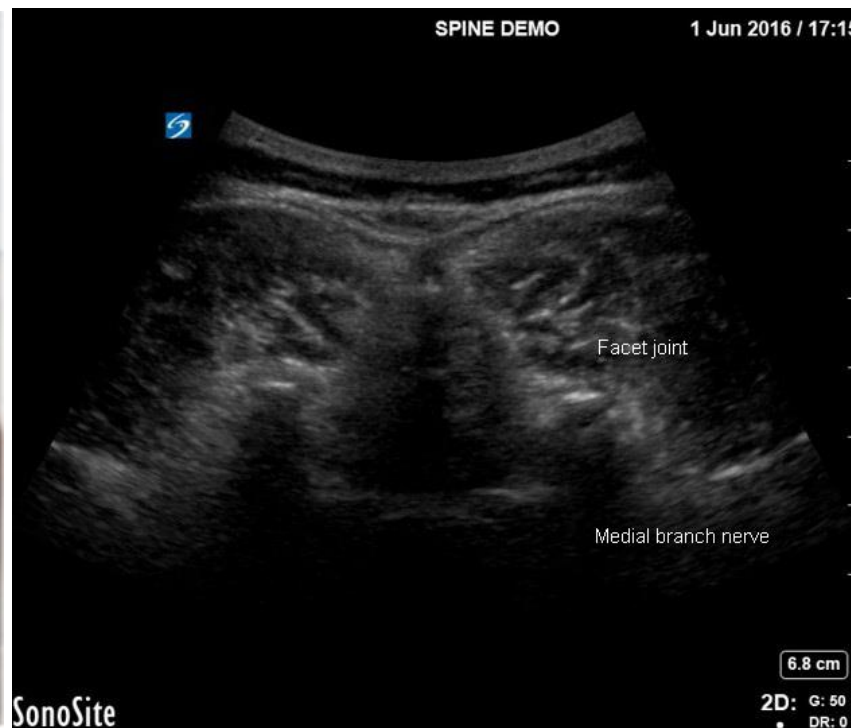
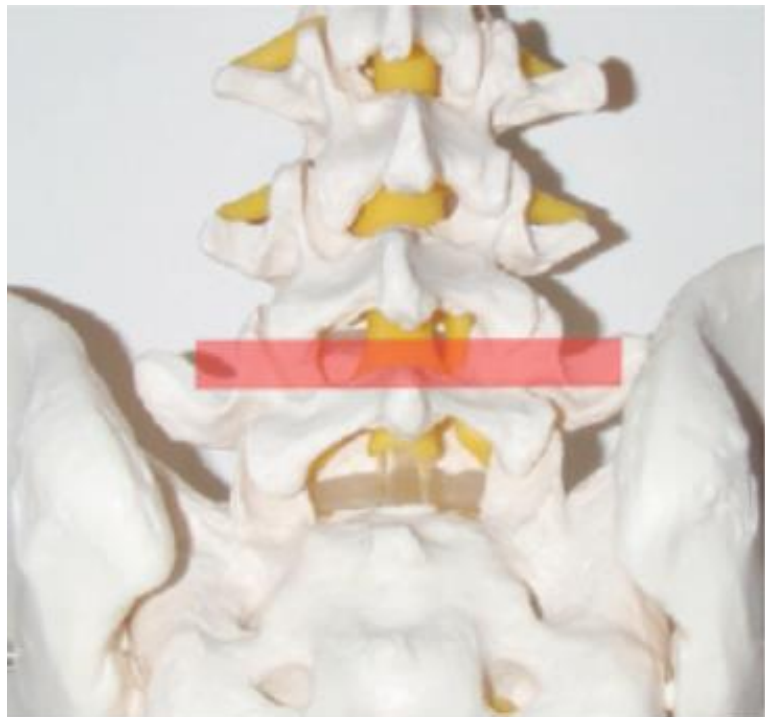
## Scanning technique- 從中到外



Trident sign

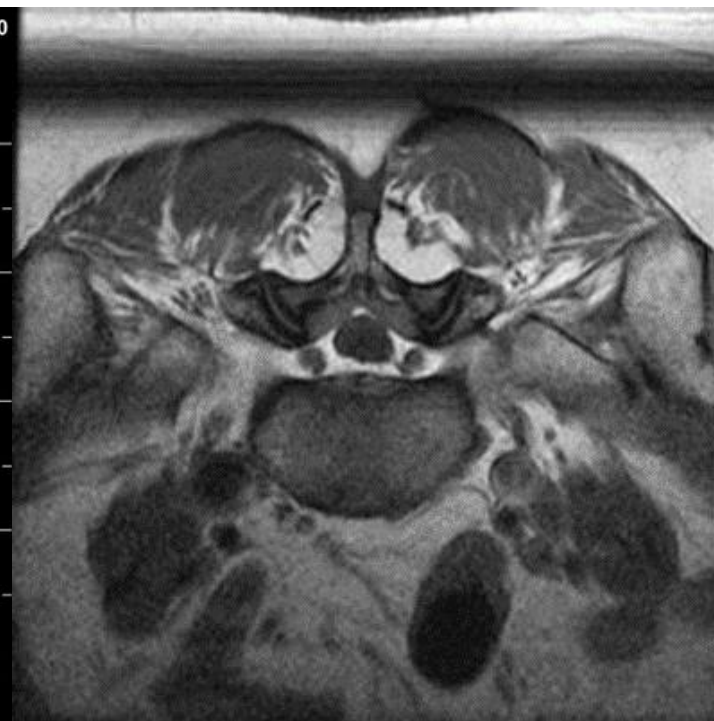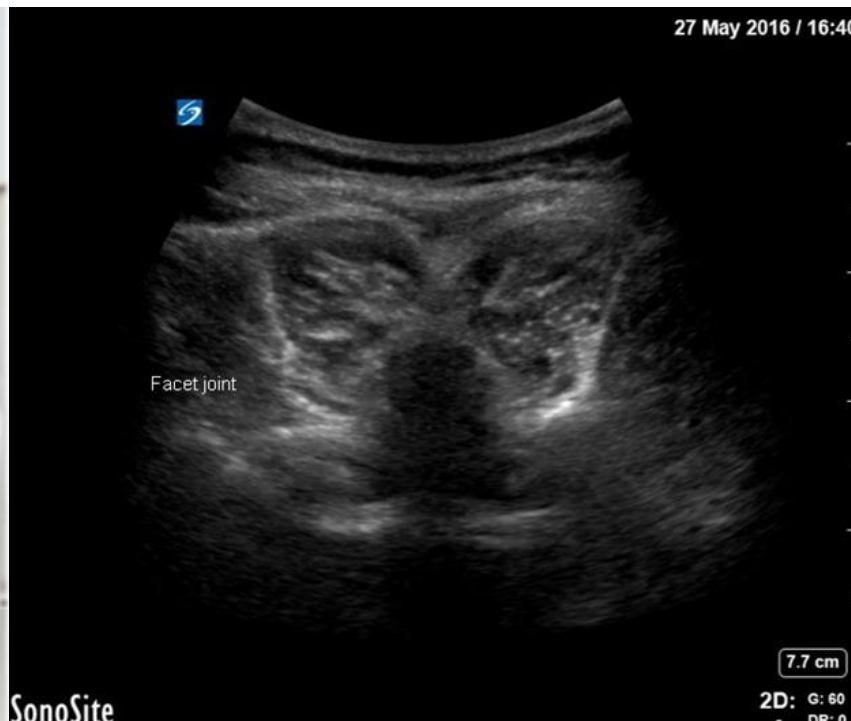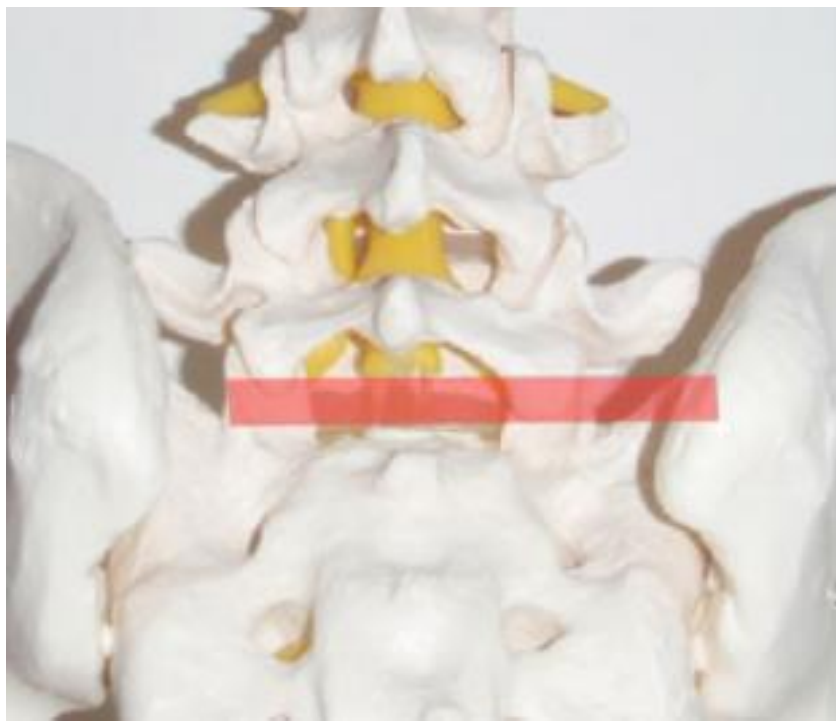
# Facet joints and the medial branch nerves

## Scanning technique-從頭到腳

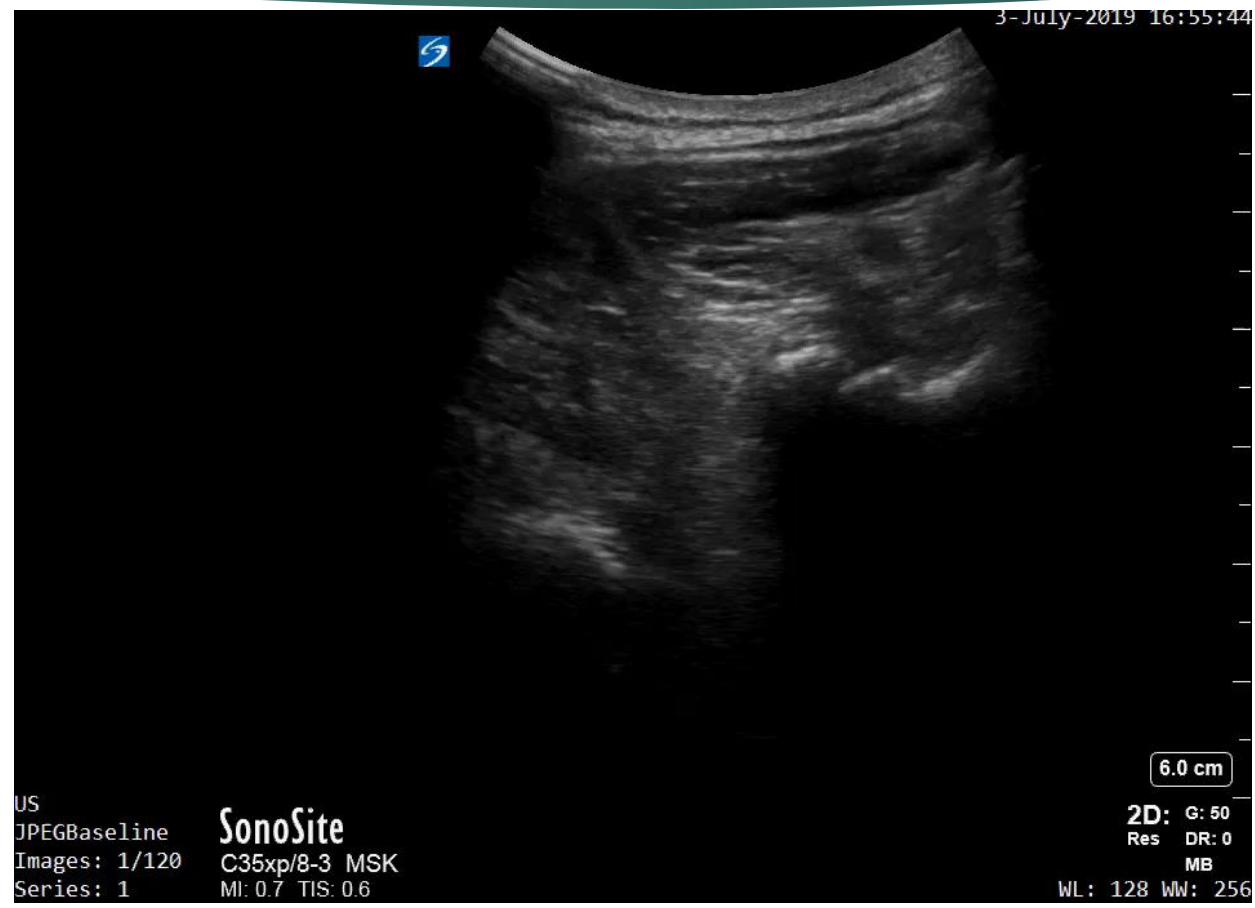

# Facet joints and the medial branch nerves

## Scanning technique- 從頭到腳

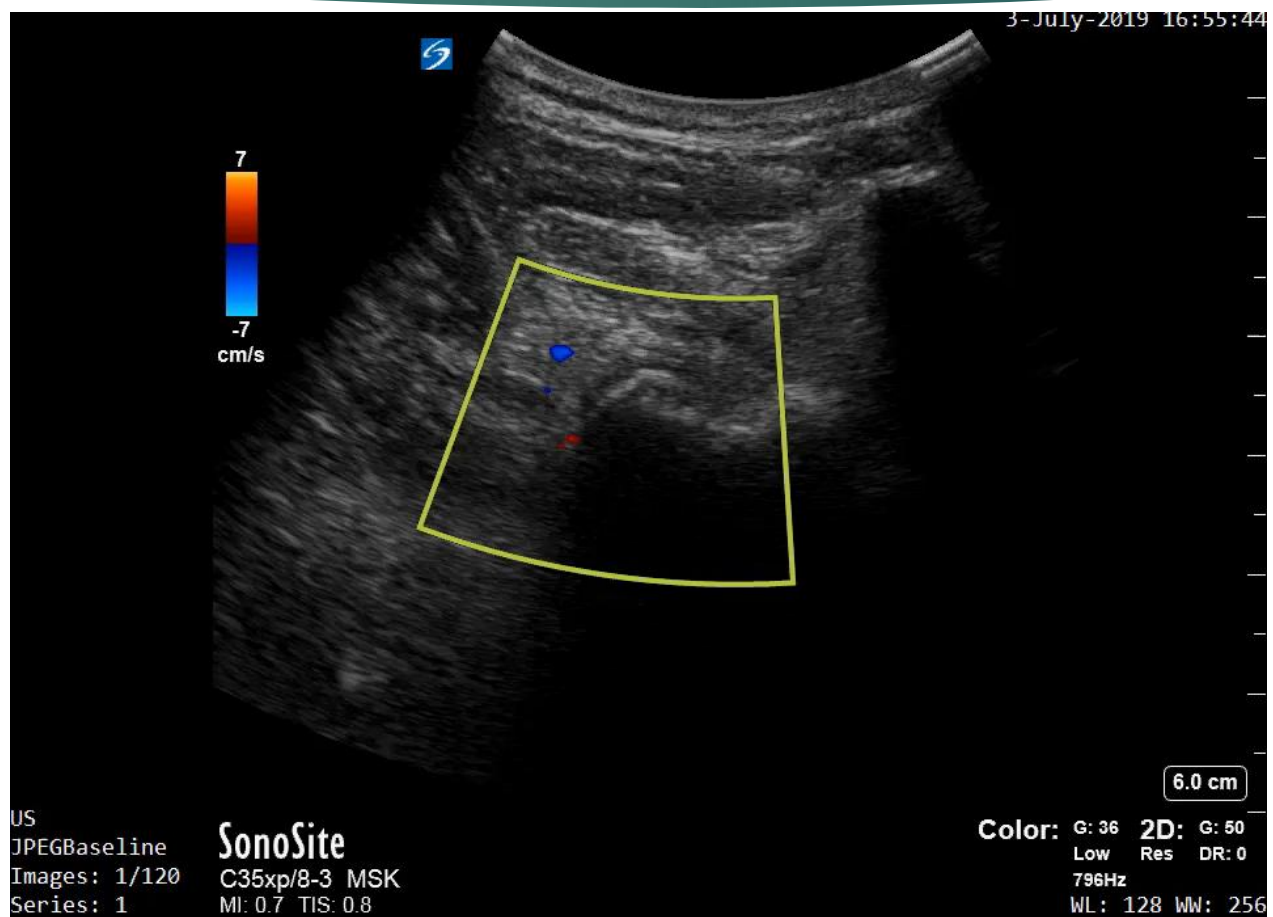


# Always easy

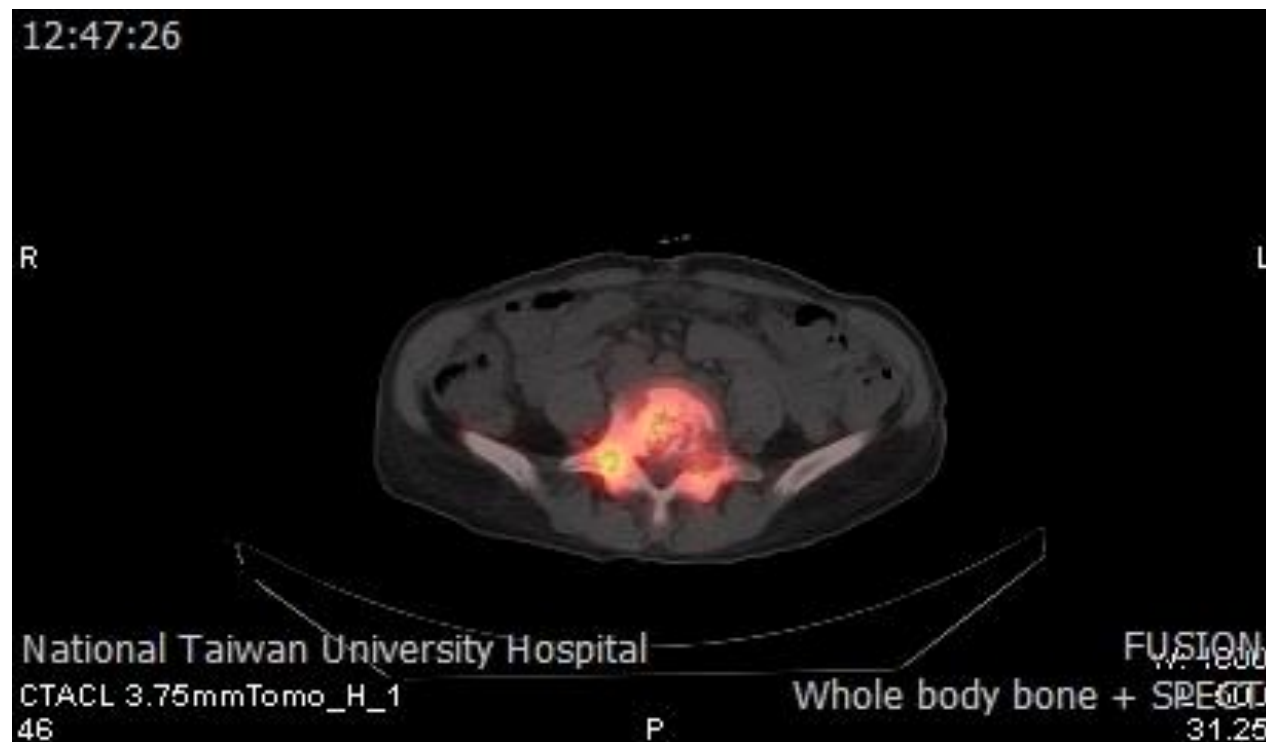
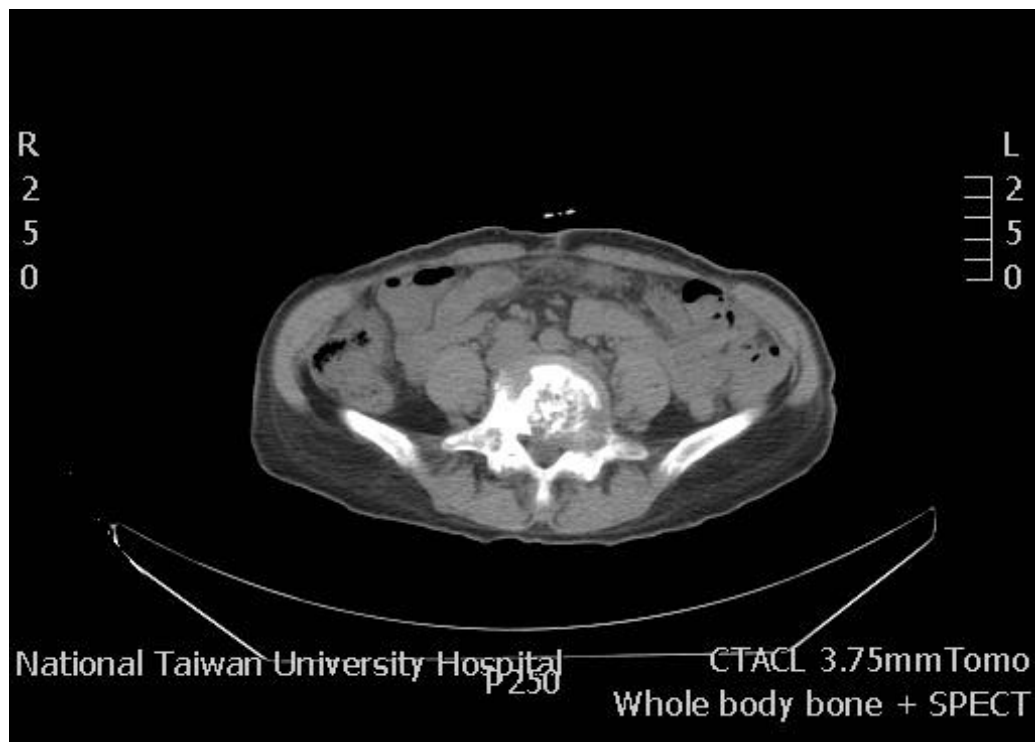




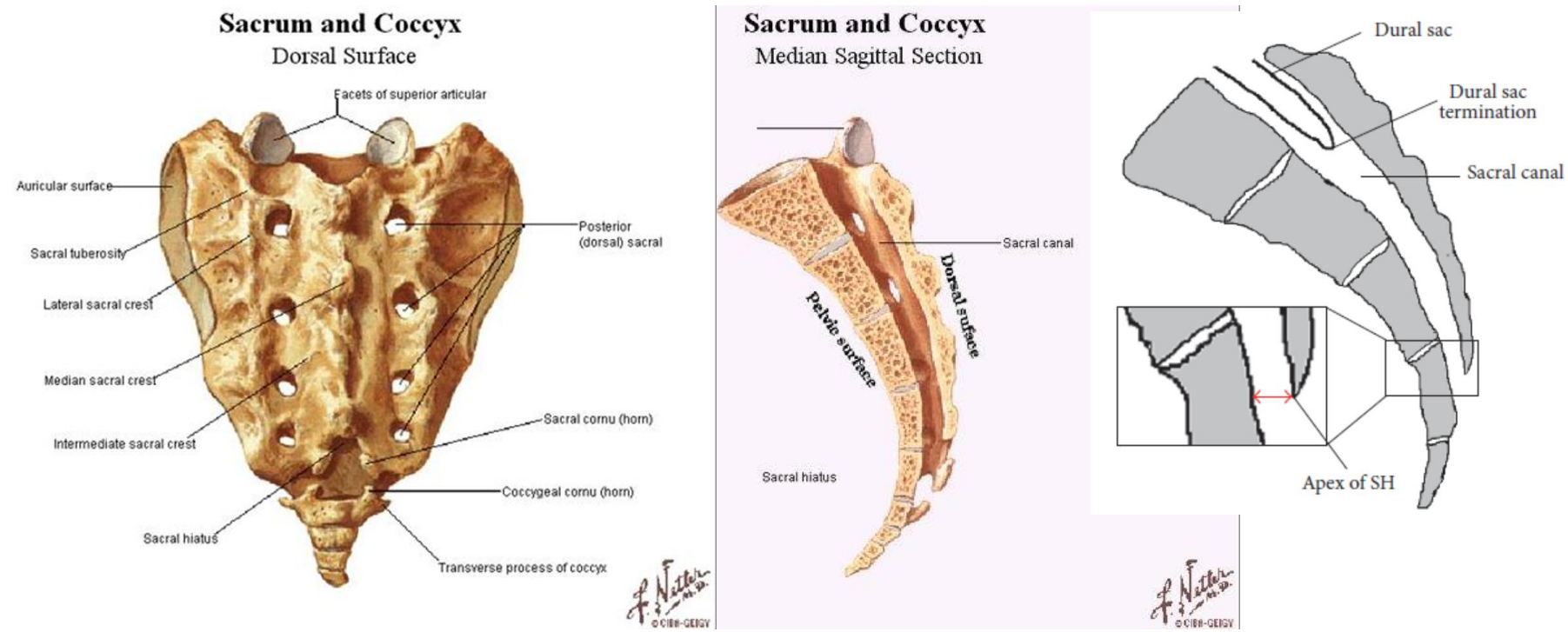
# Always safe?



# Metastatic tumor



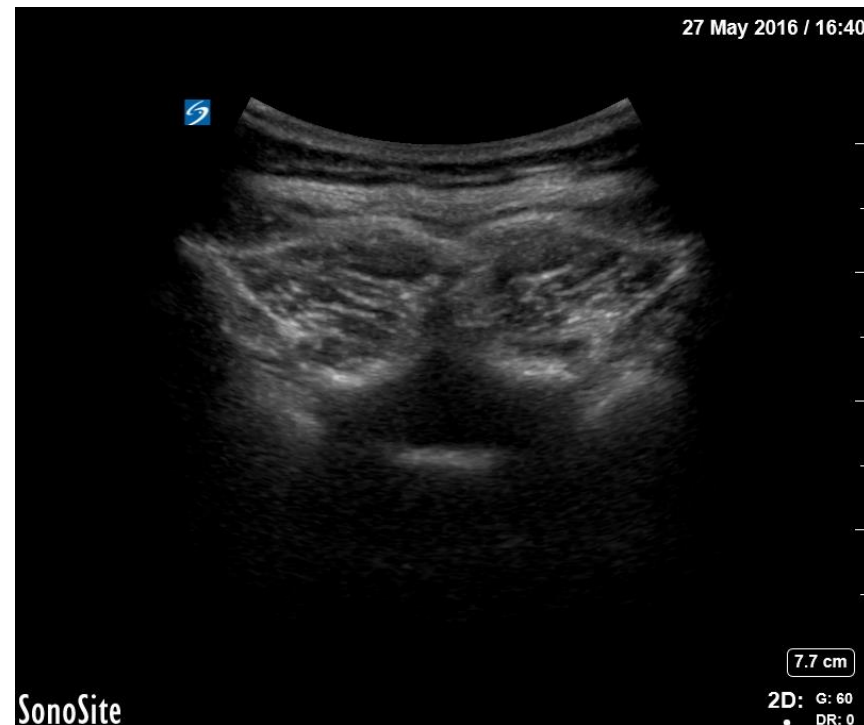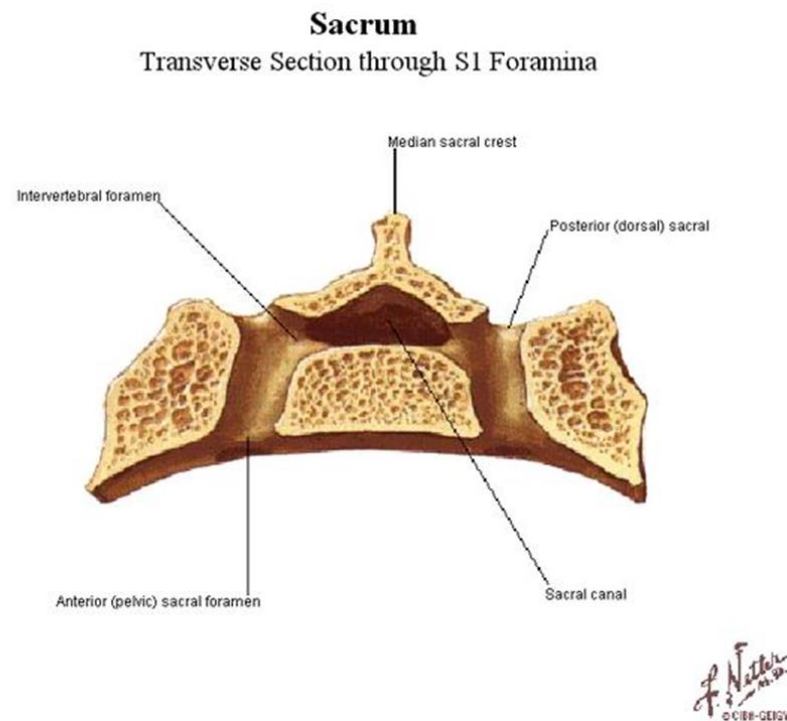
# Sacral foramen- Anatomy



Kao SC, Lin CS. Caudal Epidural Block: An Updated Review of Anatomy and Techniques. *Biomed Res Int.* 2017

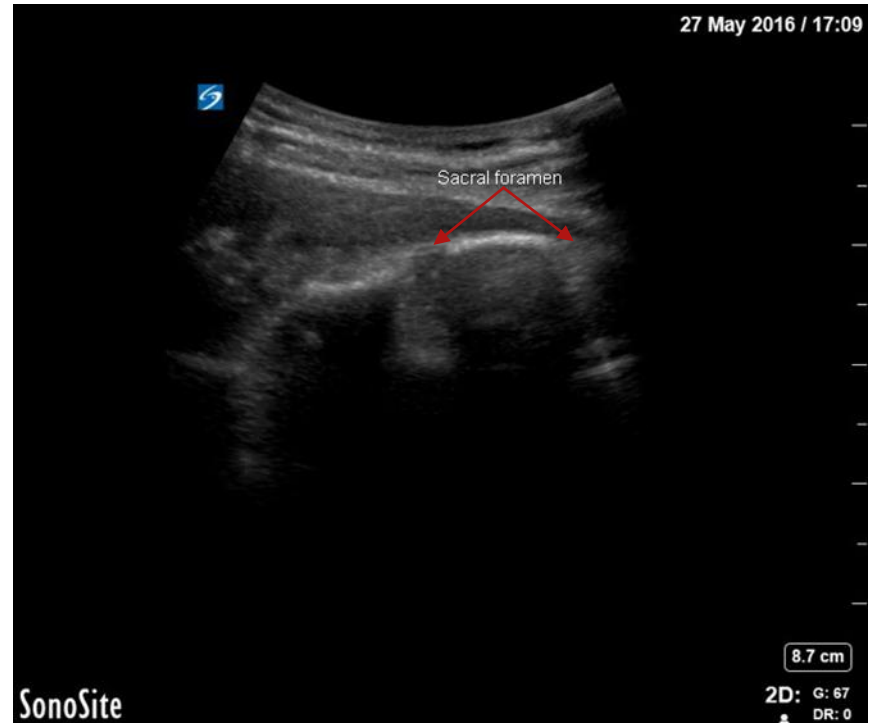
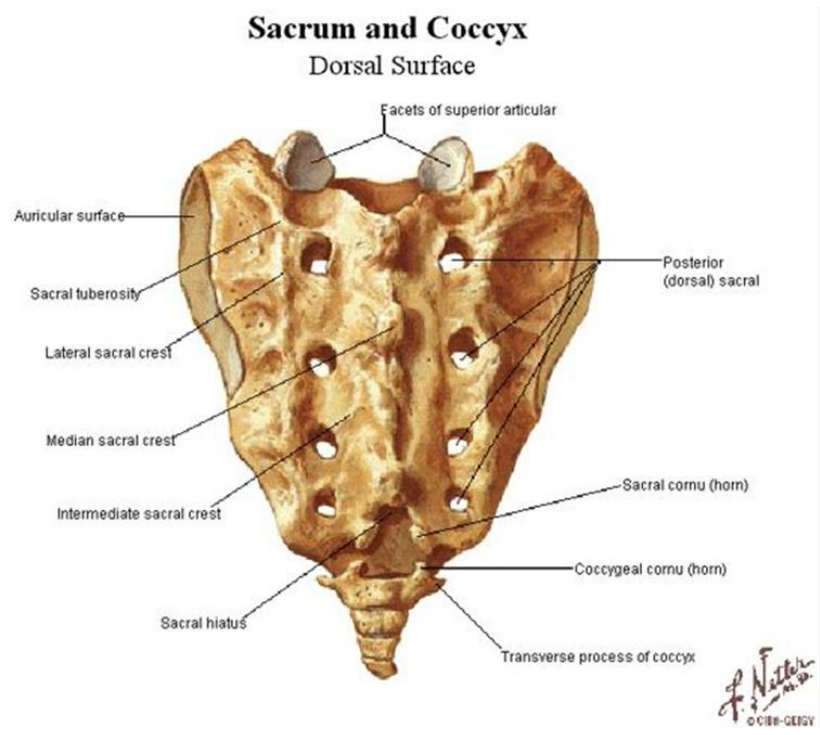
# Sacral foramen

## Scanning technique



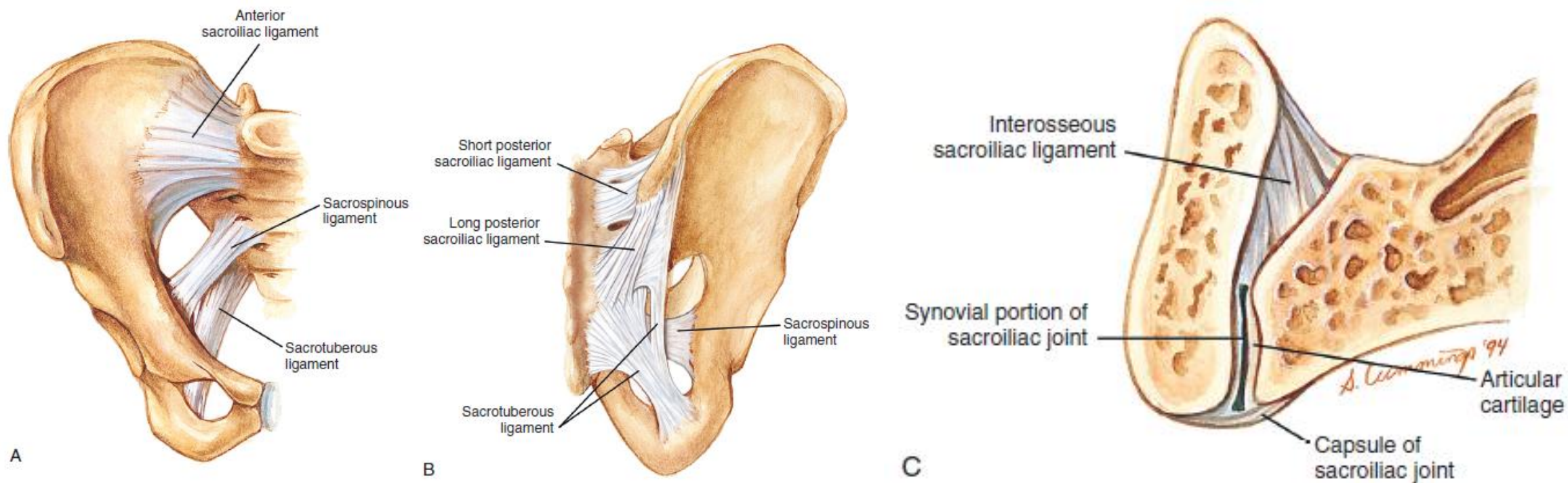
# Sacral foramen

## Scanning technique- 2&3最淺



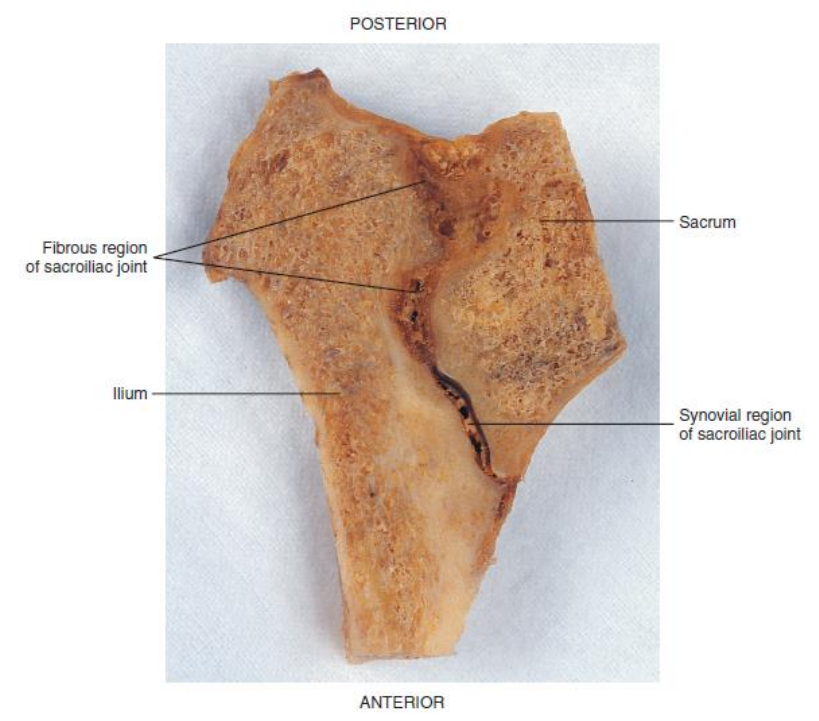
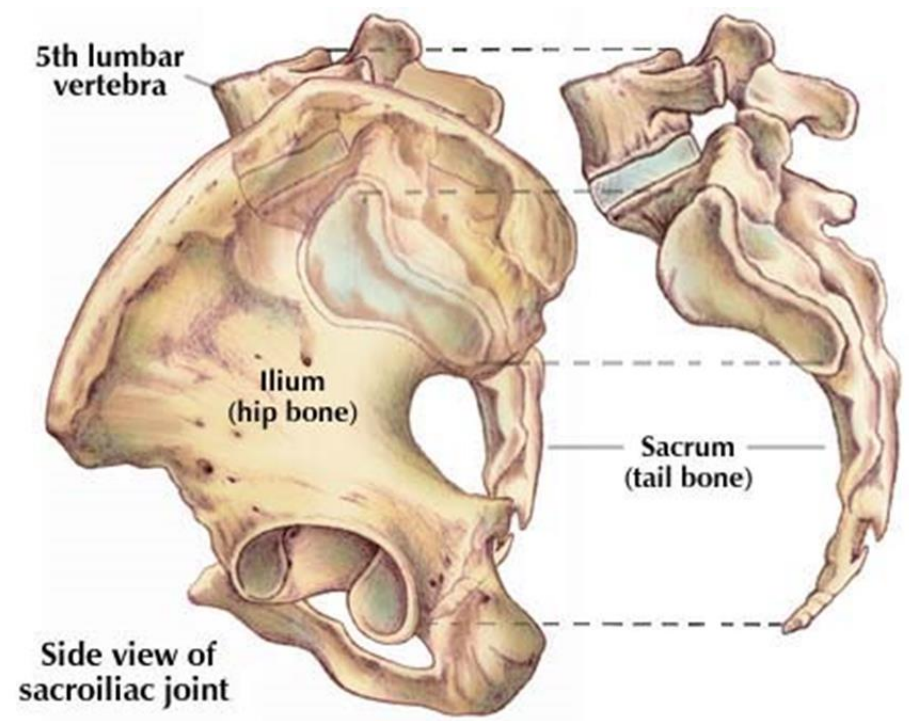


# SI joint injection- **Anatomy**

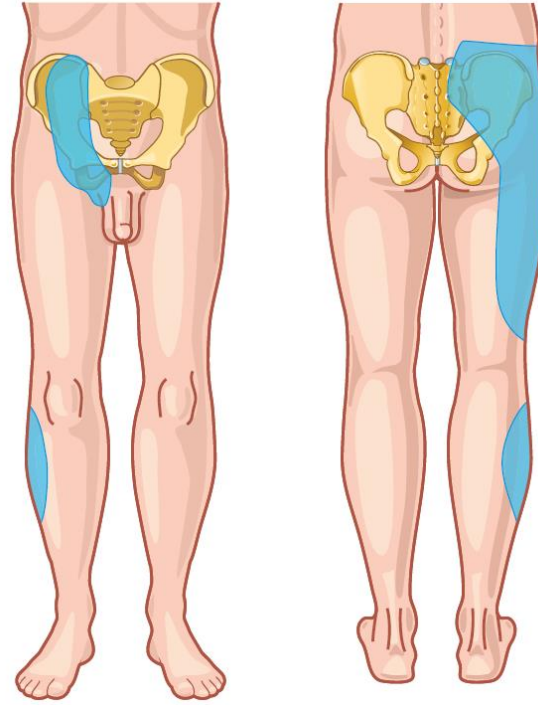
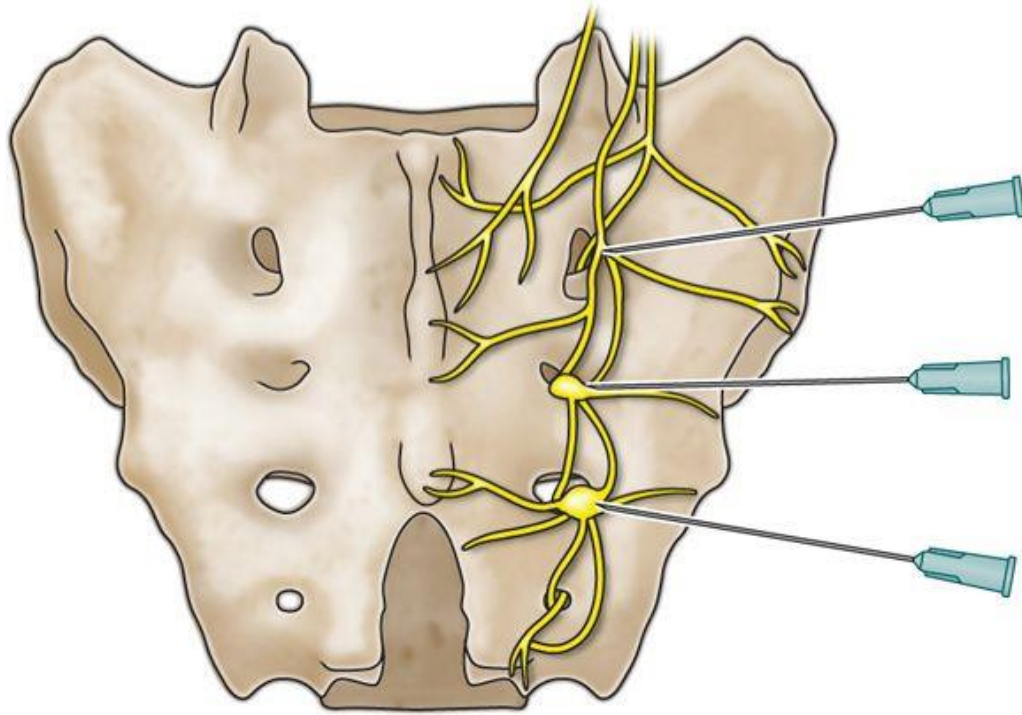


Steven D. Waldman, MD. (2021). *Atlas of Interventional Pain Management, 5th Edition*. Elsevier Publications.

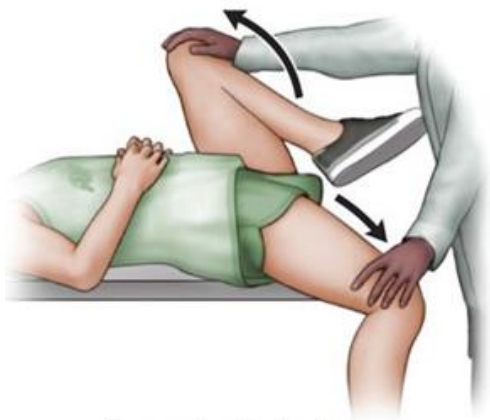
# SI joint injection- **Anatomy**



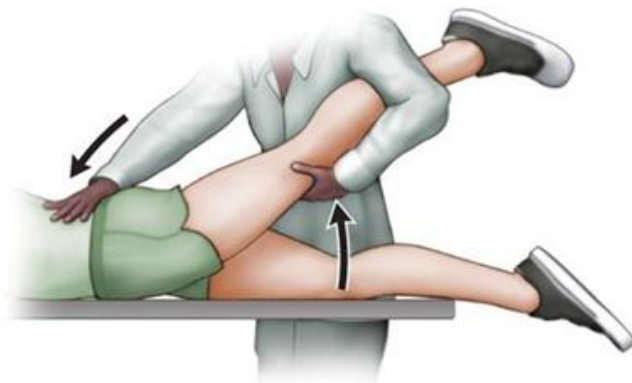
# SI joint injection- **Anatomy**



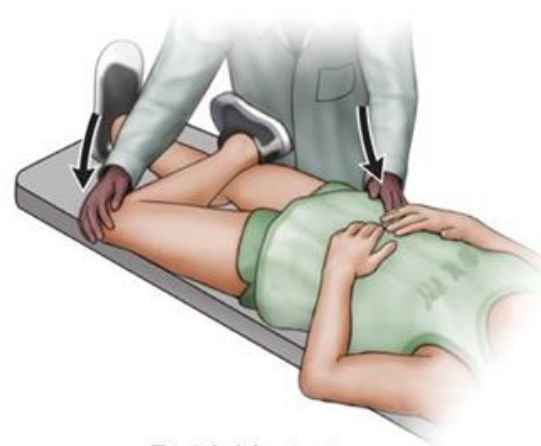# Provocative tests of SI joint



Gaenslen's test



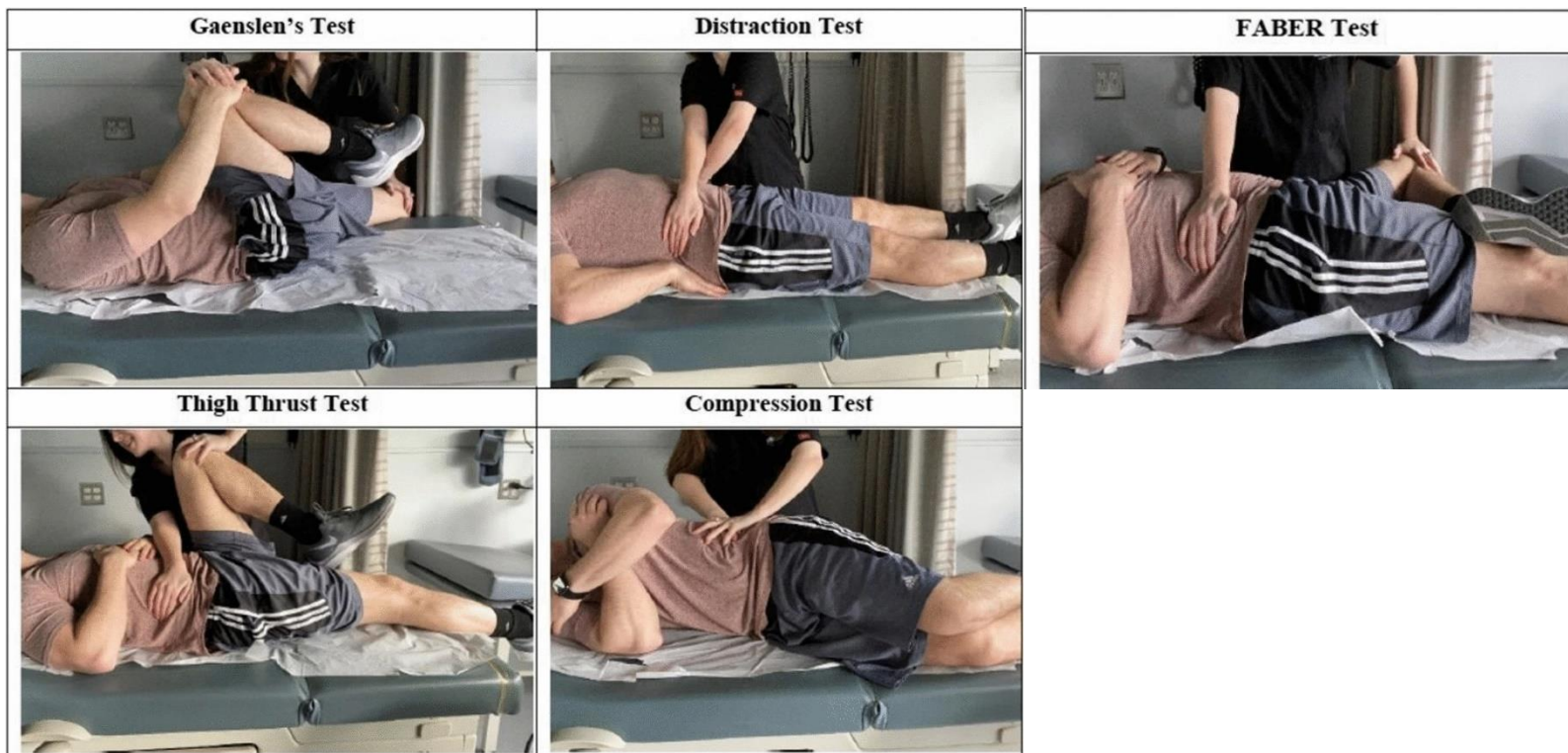
Yeoman's test



Patrick's test



# Provocative tests of SI joint

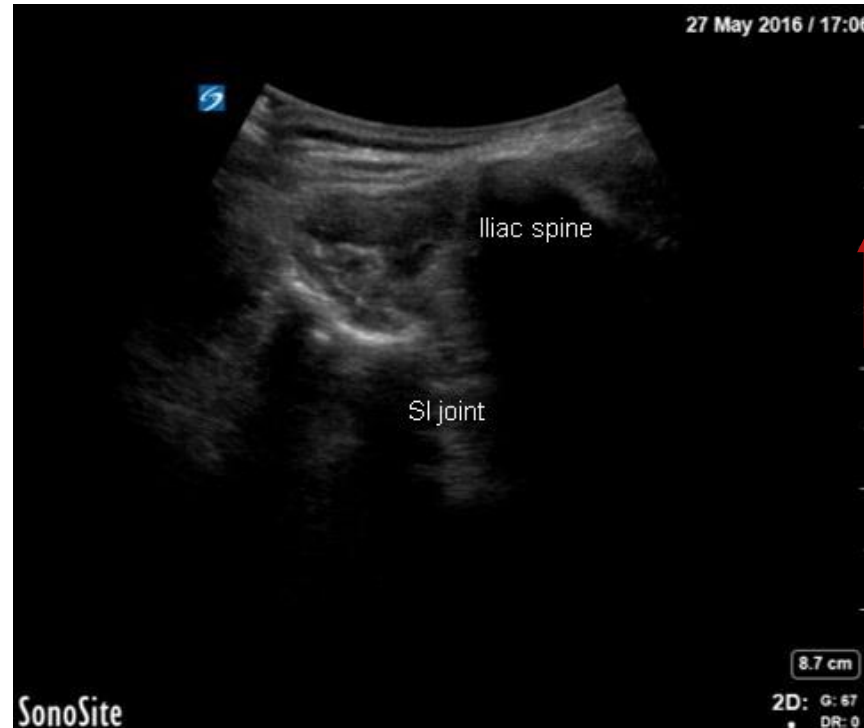
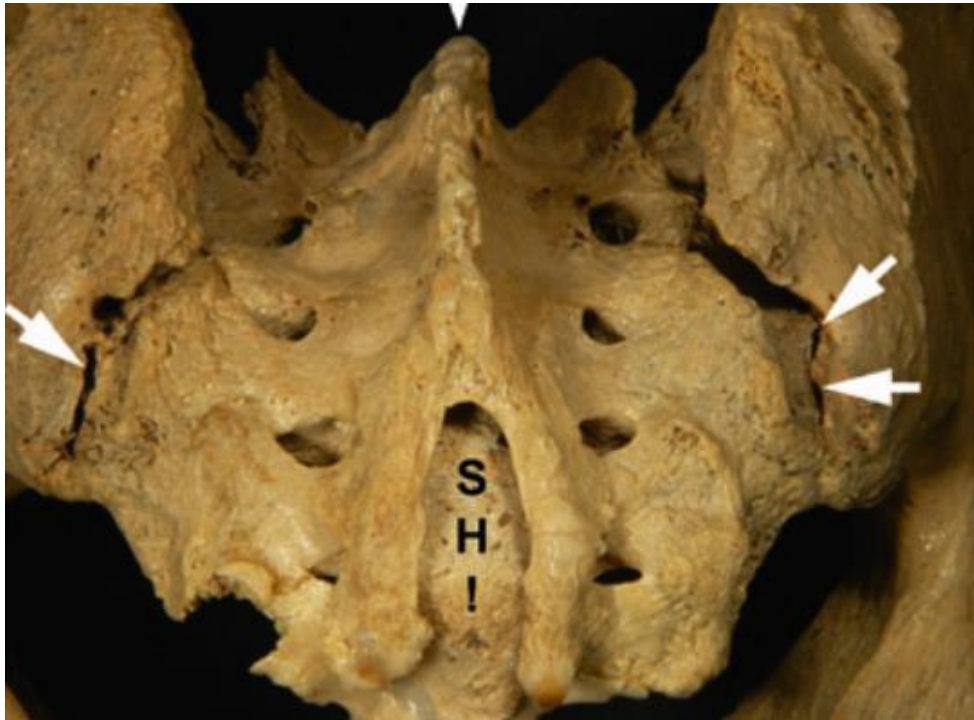
Gartenberg A, *et al.* Sacroiliac joint dysfunction: pathophysiology, diagnosis, and treatment. *Eur Spine J.* 2021 Jul 16. doi: 10.1007/s00586-021-06927-9. Online ahead of print.



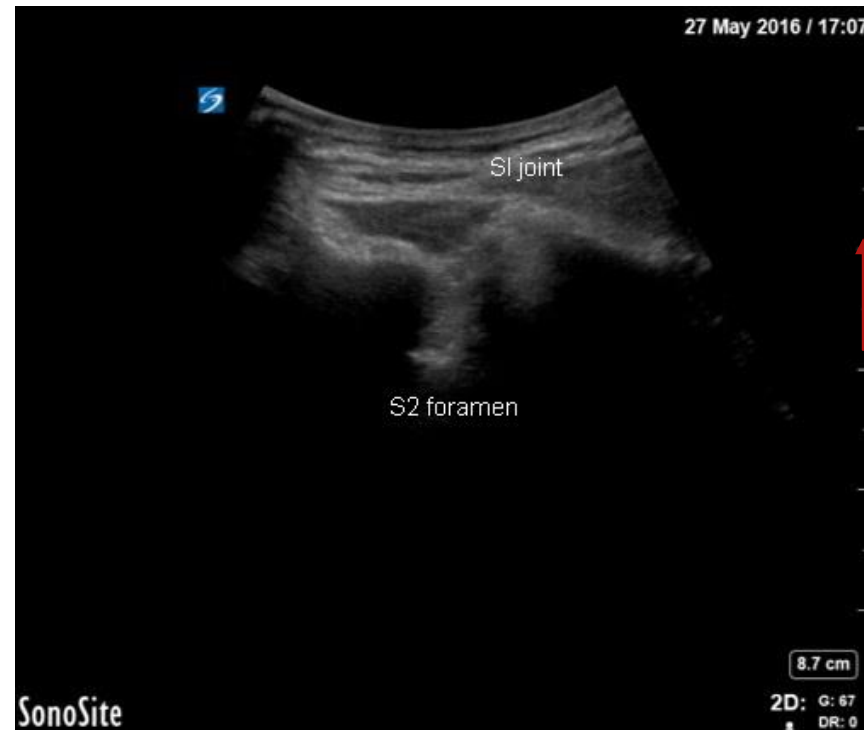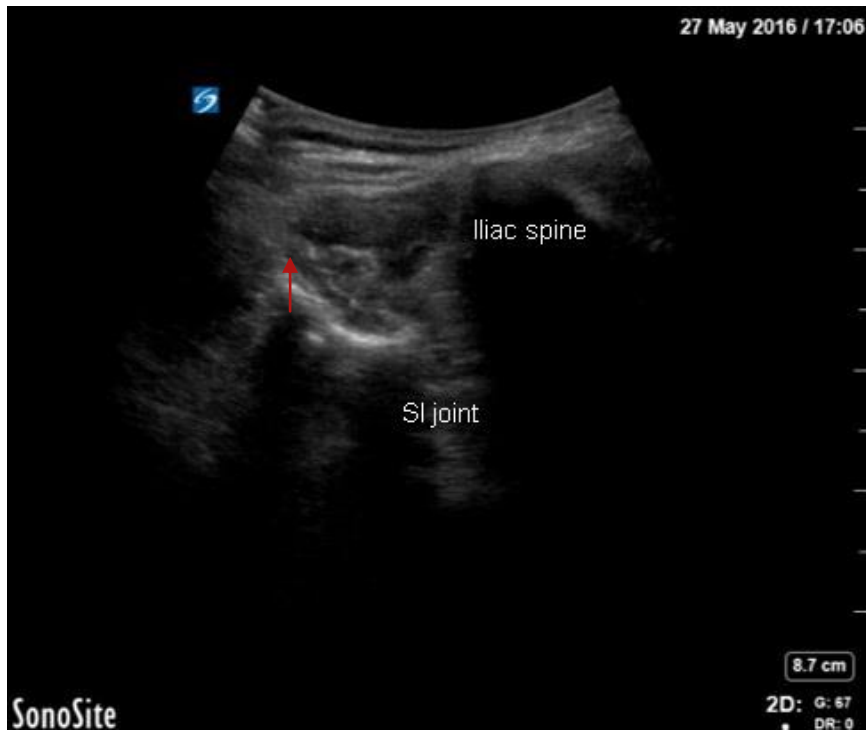# SI joint injection

Scanning technique- 先找小洞



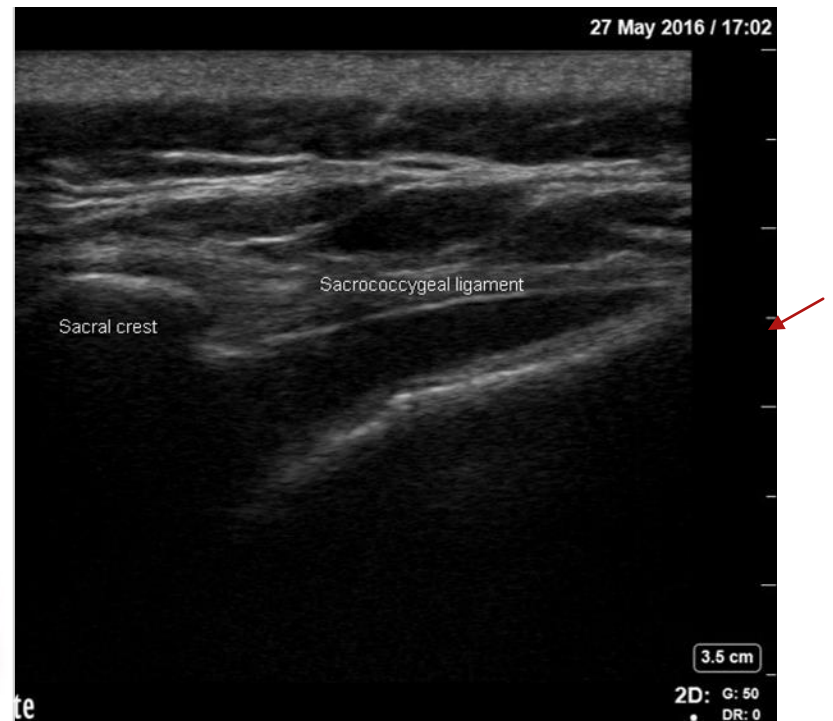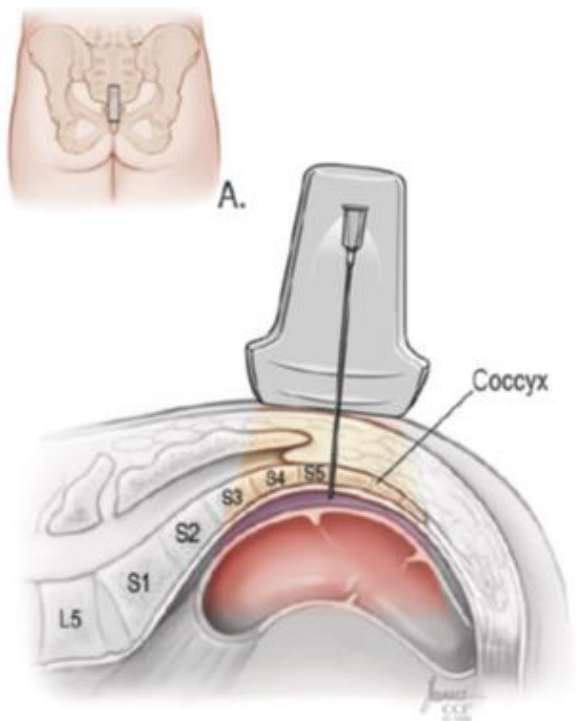
# SI joint injection

Scanning technique- 先找小洞



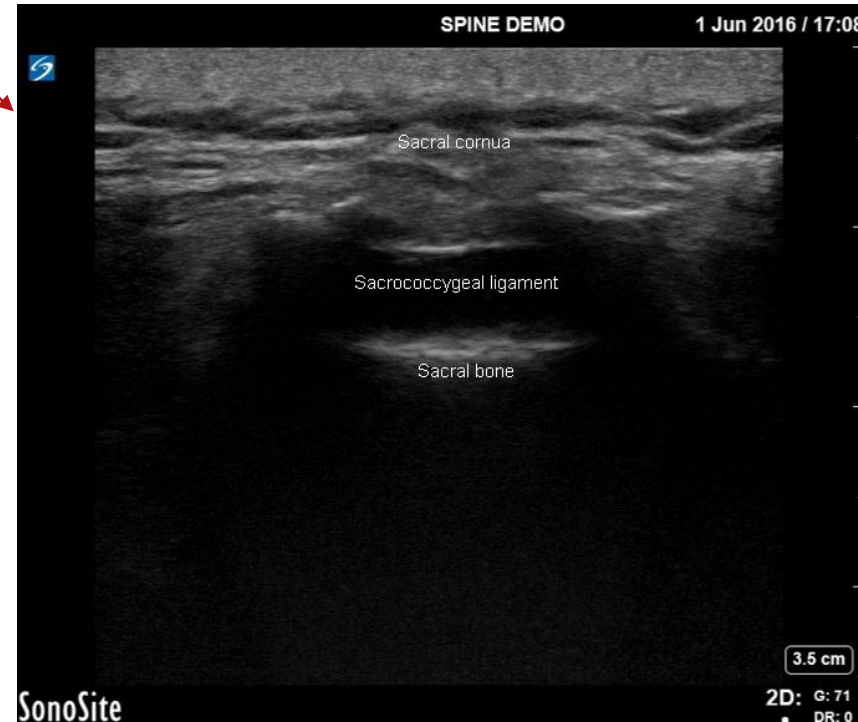
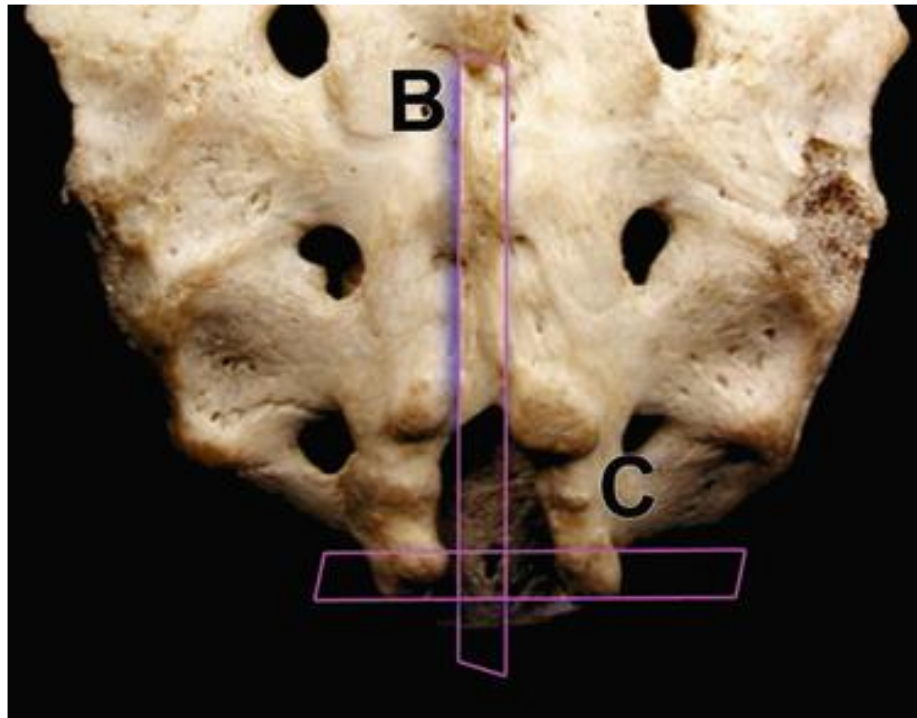
# Caudal injection

## Scanning technique

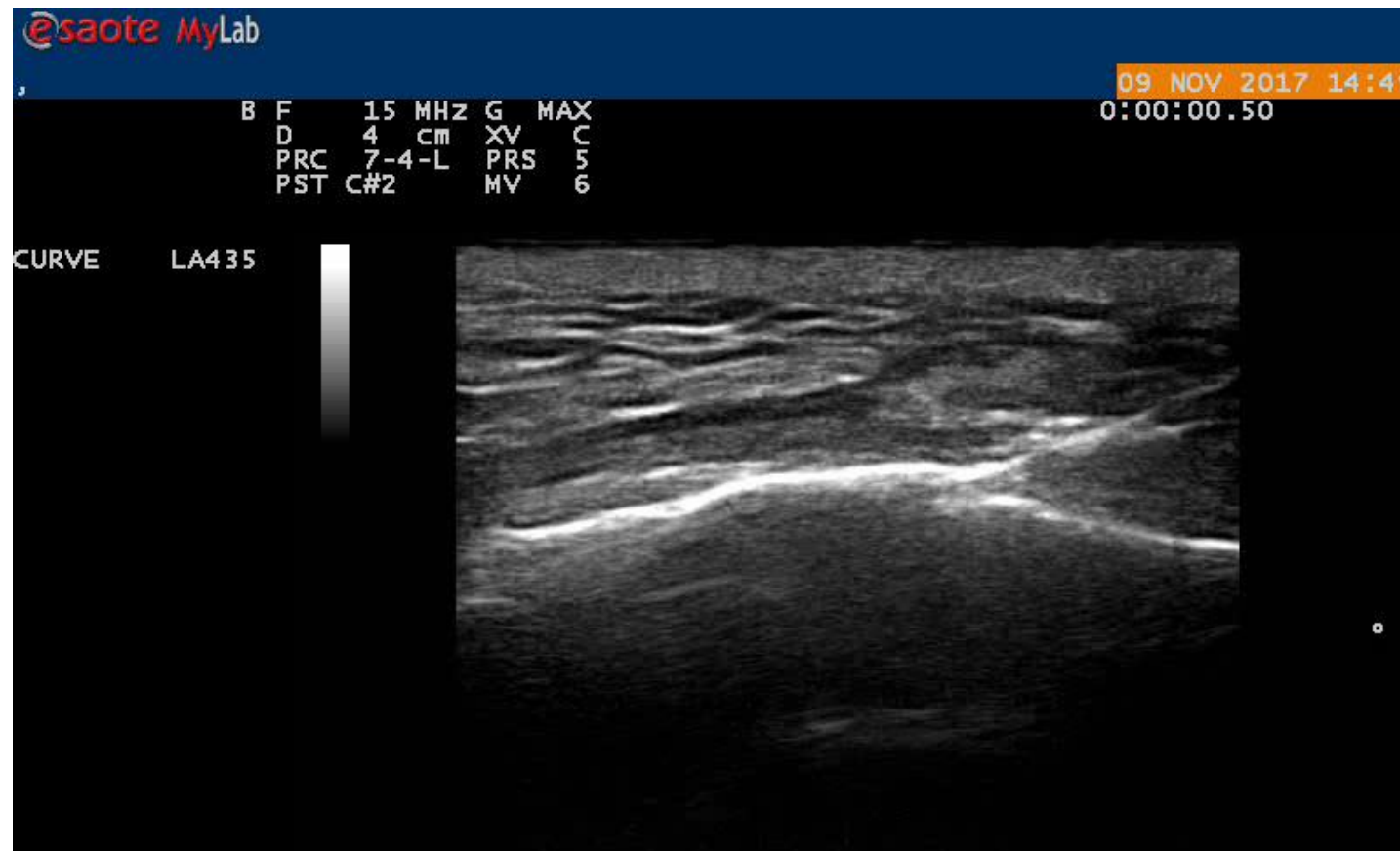

# Caudal injection

## Scanning technique



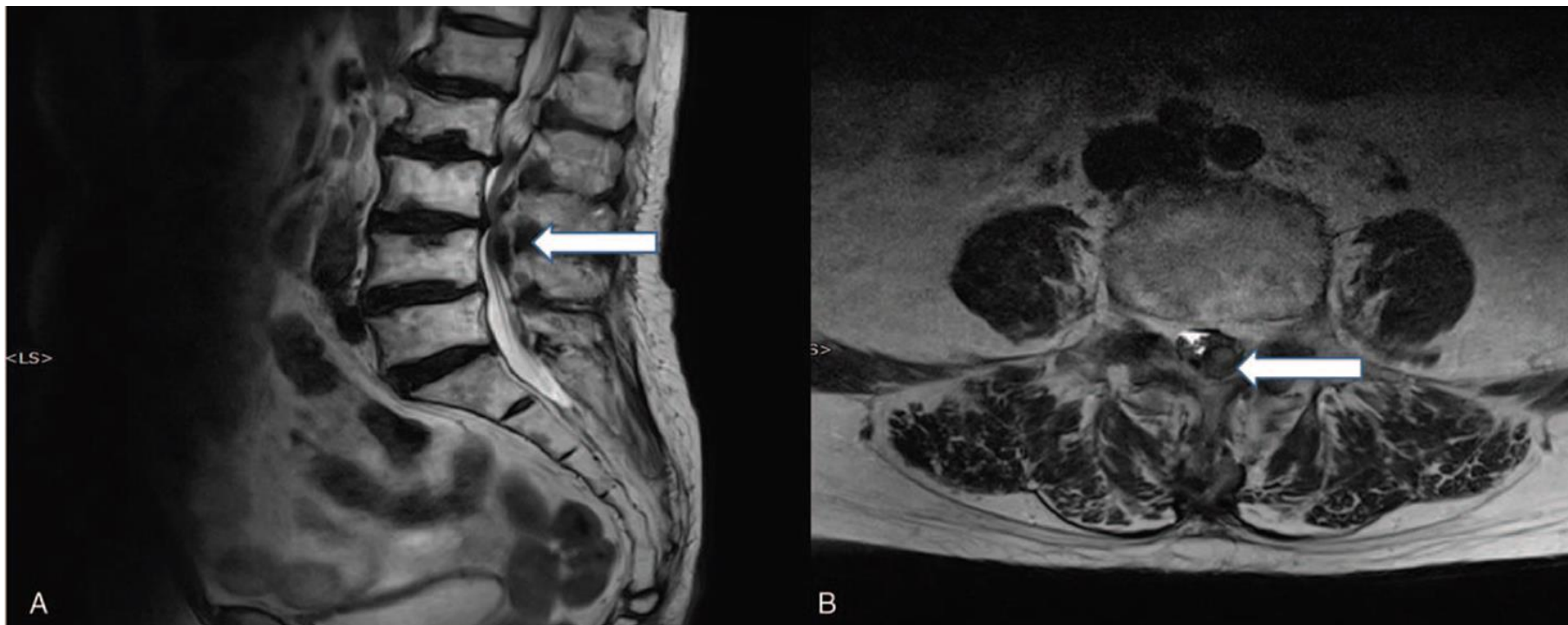
# Caudal injection Always easy?





# Caudal injection

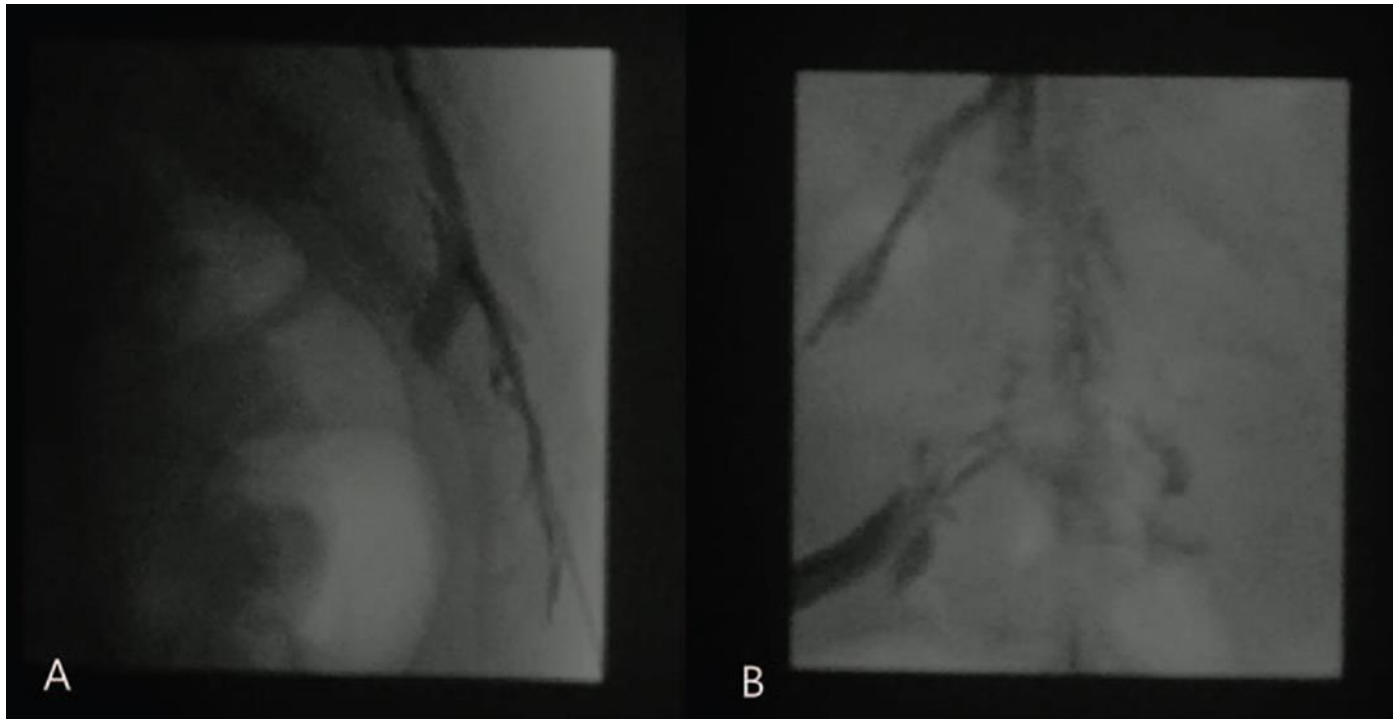
## Always safe?



Choi JJ, *et al.* Discordant lumbar epidural hematoma after caudal steroid injection: A case report (CARE-compliant). *Medicine (Baltimore)*. 2017 Jun;96(24):e7127

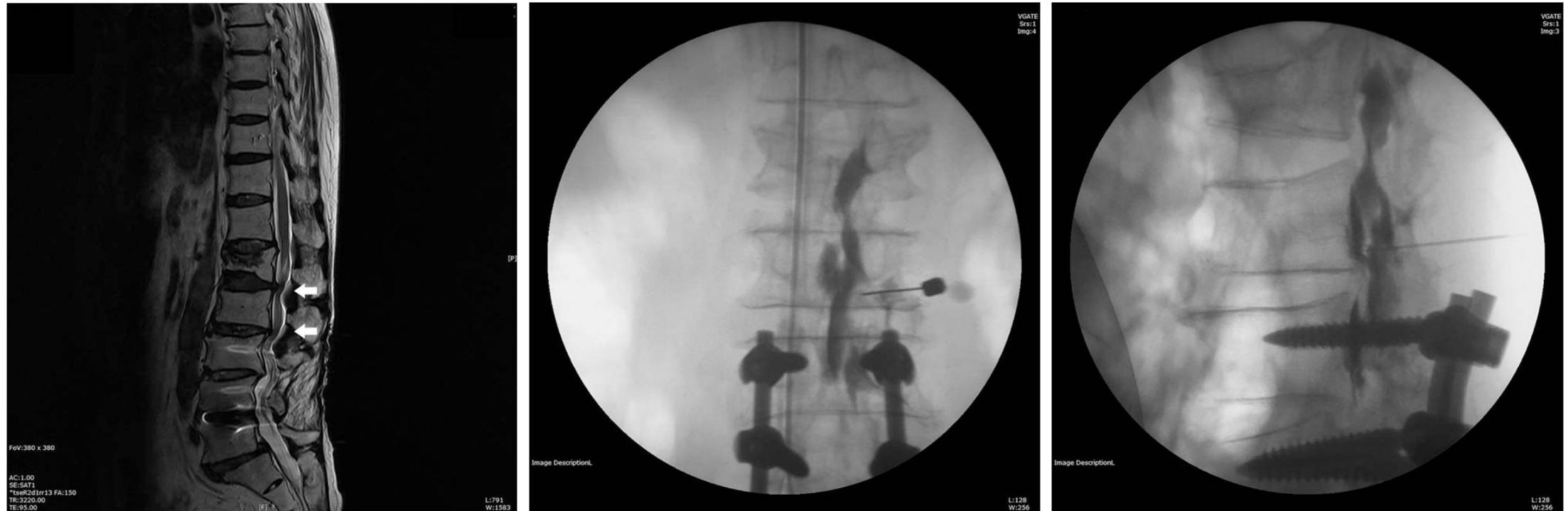# Caudal injection

## Always safe?



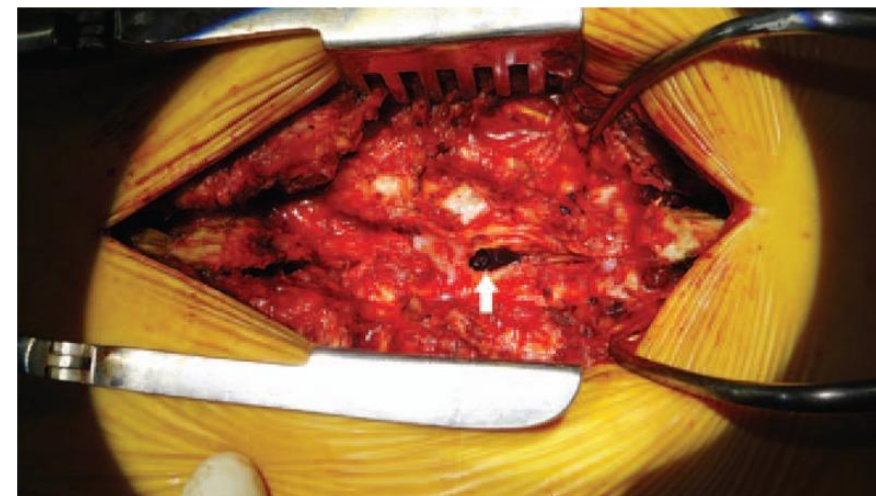
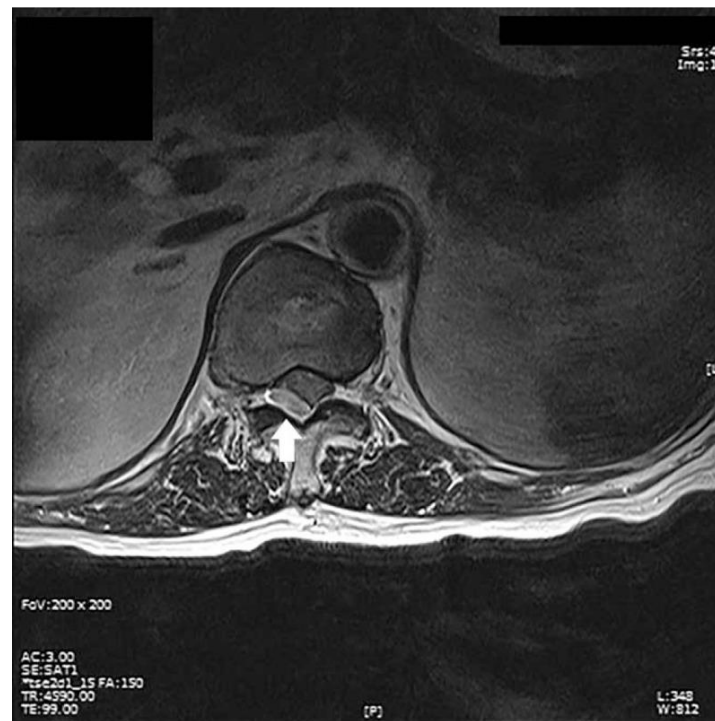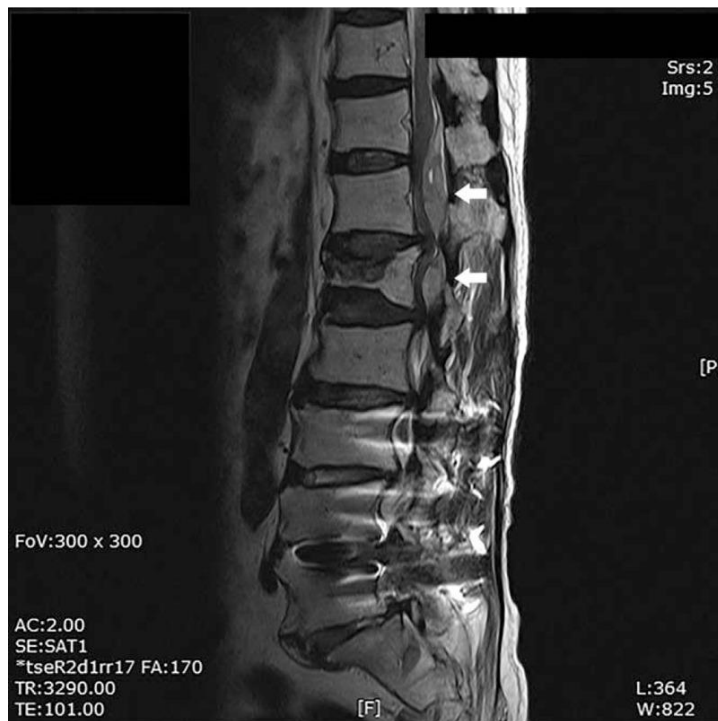Choi JJ, *et al.* Discordant lumbar epidural hematoma after caudal steroid injection: A case report (CARE-compliant). *Medicine (Baltimore)*. 2017 Jun;96(24):e7127

# Transforaminal injection



Kim, Sang-In, *et al.* Spinal epidural hematoma occurring at a distance from the transforaminal epidural injection site: A case report. *Medicine (Baltimore)*. 2019 Jul;98(30):e16654.

# Transforaminal injection



Kim, Sang-In, *et al.* Spinal epidural hematoma occurring at a distance from the transforaminal epidural injection site: A case report. *Medicine (Baltimore)*. 2019 Jul;98(30):e16654.