

Original Article

Results of revision total hip arthroplasty with cementless cups with different coating

Yen-Wen Cheng^{a,b}, Wei-Ming Chen^{a,b,*}, Cheng-Fong Chen^{a,b}, Chao-Ching Chiang^{a,b}, Ching-Kuei Huang^{a,b}, Chien-Lin Liu^{a,b}, Tain-Hsiung Chen^{a,b}^a Department of Orthopedics and Traumatology, Taipei Veterans General Hospital, Taipei, Taiwan^b Department of Orthopedics and Institute of Clinical Medicine School, National Yang-Ming University, Taipei, Taiwan

ARTICLE INFO

Article history:

Received 31 July 2011

Received in revised form

2 May 2012

Accepted 10 May 2012

Available online 22 August 2012

Keywords:

aseptic loosening

fiber-metal-coated cups

hydroxyapatite-coated cup

porous-coated cup

revision total hip arthroplasty

ABSTRACT

Background/Purpose: Revision total hip arthroplasty has become more and more challenging in recent years due to the lengthened lifespan of the patients and greater number of revision total hip surgeries. The hydroxyapatite (HA)-coated cup was reported to reduce the radiolucent line after total hip arthroplasty. However, it was also reported that HA particles increased the risk of polyethylene (PE) liner wear, resulting in osteolysis. Therefore, we wanted to know which cup coating would result in a lower loosening rate and better longevity after revision total hip surgery.

Methods: We reviewed a series of revision total hip arthroplasties in our department from 2000 to 2009. A total of 321 patients underwent 374 revision hip arthroplasties with cup replacement. Cases of revision total hip arthroplasty with cup revision caused by aseptic loosening were included in our study. In all, 148 cases fulfilled our criteria and were enrolled into our study. Revision due to aseptic loosening after prior revision surgery was defined as $[(\text{lifespan of revision implant}) < \text{comment}]$. This appears to be a comment left from Elsevier. We checked the revision rate and implant longevity of HA-coated TRIDENT (Stryker, Mahwah, NJ, USA), porous-coated DURALOC (Depuy, Warsaw, IN, USA) and fiber-metal-coated TRILOGY (Zimmer, Warsaw, IN, USA) cups after revision hip arthroplasty.

Results: Of the 148 cases, 73 were revised with HA-coated, 32 with porous-coated and 43 with fiber-metal-coated cups. Fiber-metal coating, to a significant extent, had the highest incidence rate and shortest implant survival of the three groups. In terms of high degrees of pre-operative acetabular defects, HA-coating and porous coating preserved more bone stock than fiber-metal coating.

Conclusion: HA-coated implants were regarded as beneficial to bone ingrowth after hip arthroplasty, especially with regard to the cup and stem components. Porous-coated cups had similar results. Fiber-metal-coated cups had a significantly higher loosening rate and lower implant survival, especially with large pre-operative acetabular bone defects with Paprosky classifications IIIA and IIIB.

Revision total hip arthroplasty with HA-coated or porous-coated cup components revealed better results, greater longevity, and a low incidence of repeated revision, especially in cases with large bone defects. Copyright © 2012, Taiwan Orthopaedic Association. Published by Elsevier Taiwan LLC. All rights reserved.

1. Introduction

Total hip arthroplasty (THA) is one of the most effective orthopedic operations of recent years. However, the longevity of THA has been taken into consideration because of the prolonged lifespan of the patients.¹

Generally speaking, THA requires revision in circumstances that include infection, periprosthetic fracture, recurrent dislocation, liner wear, osteolysis, and most common of all, aseptic loosening.² Osteolysis is a very important factor related to the longevity of arthroplasty. Osteolysis may occur as a result of various mechanisms, but particles from a worn liner play a big role. Polyethylene (PE) particles from the liner may induce backside wear and third body wear.³ Newly designed PE and highly cross-linked PE can reduce liner wear. Other bearing materials, such as ceramic on ceramic, metal on metal, or ceramic on PE are able to decrease osteolysis from PE particles.⁴ Liner problems are improving

* Corresponding author. Department of Orthopedics, Taipei Veterans General Hospital, 201, Section 2, Shih-Pai Road, Taipei 112, Taiwan. Tel.: +886 2 28757557x117; fax: +886 2 28757559.

E-mail address: wmchen@vghtpe.gov.tw (W.-M. Chen).

Table 1
Implant profile.

Implant	Coating	Liner	Manufacturer
TRILOGY	Fiber metal	Longevity	Zimmer, Warsaw, IN, USA
TRIDENT	Hydroxyapatite	Crossfire X3	Stryker, Mahwah, NJ, USA
DURALOC	Porous	Altralink	Depuy, Warsaw, IN, USA

gradually. Another important factor of osteolysis is cup design. Different cup designs, especially different coatings, lead to different results in THA. Coating material may be the key factor in different cup designs. We often use porous coating, hydroxyapatite (HA) coating or fiber-metal coating acetabular components for THA. Choice of coating material is still debated and most investigations have focused on primary hip arthroplasty with different coatings. No large series report on coating material in revision hip arthroplasty can be found.

Besides, bone loss after repeated revision hip arthroplasties is challenging during operation. Acetabular bone defects after hip arthroplasty affect the revision surgery and operative method.⁵ Bone stock preservation is another important issue in revision hip arthroplasty. An ideal implant should have the following characteristics: good bone purchasing, a low failure rate, and bone stock preservation.⁶ The HA-coated femoral stem is widely used in revision THA and has proved to be very successful. However, the issue of which cup coating provides better results for revision THA is still debated. Therefore, we wanted to know if different kinds of coating on the cups would yield different results in revision THA.

2. Materials and methods

The purpose of this study was to investigate retrospectively the long-term follow-up of patients who had undergone revision THA. For patients with THA with different types of cups, we wanted to know the revision rate due to aseptic loosening, implant longevity, and bone stock preservation after the first revision surgery. All patients underwent revision hip arthroplasty by a single surgeon (W.M.C.) from 2000 to 2009. The same operative approach and soft-tissue dissection was used in all surgeries. All patients achieved initial stability postoperatively and were followed at least two years. Our inclusion criterion was that the patients had undergone revision hip arthroplasty or a revised acetabular component operation due to aseptic loosening. Those patients with the following were excluded: infection, periprosthetic fracture, recurrent dislocation, which required revision, liner wear without loosening, revision with a cemented technique, or revision required due to neoplasm. The endpoint of the implant was defined as it being loosened enough to be revised, based on imaging findings. We measured bone stock using Paprosky acetabular classification. The implants used included the porous-coated DURALOC (Depuy,

Table 2
Demographic data.

	HA	Porous	Fiber Metal
Sex, N (M/W)	73 (35/38)	32 (13/19)	43 (12/31)
Mean age, y (min/max)	59.23 (26/83)	62.49 (33/85)	57.51 (26/84)
Loosening numbers	6	3	11
Mean follow-up (mo)	38.50	35.34	63.30

HA = hydroxyapatite.

Warsaw, IN, USA), HA-coated TRIDENT (Stryker, Mahwah, NJ, USA), and fiber-metal-coated TRILOGY (Zimmer, Warsaw, IN, USA). See Table 1 and Fig. 1 for more information. Choices of implant depended on several factors. First was the previous type of hip arthroplasty. When performing revision hip arthroplasty, we tried to replace the implant as little as possible to preserve more bone stock. Hence, if there was only cup loosening with a well-fixed stem, only cup revision was required. And the choice of cup was based on the original one. Some kinds of hip arthroplasty use a long stem and diaphyseal locking mechanism that makes them more appropriate for a long stem defect. Therefore, the choice of cup would change with the selection of the stem. A hybrid combination of cup and stem is permitted in certain kinds of implants.⁷ The incidence rate and bone stock preservation were calculated via Student's *t*-test, chi-square test, and *F*-test. Longevity of the implant was compared using the Kaplan-Meier method. We used MEDCALC (version 12.0.3.0) for statistical analysis.

3. Results

From 2000 to 2009, 333 revision operations were performed; 148 cases were enrolled into our study and 185 were excluded. Most of the exclusions were because of infection and periprosthetic fracture and dislocation. There were 58 men and 90 women; the mean age of all patients was 59.5 years. Forty-three hips were revised with the TRILOGY (fiber-metal-coated), 73 with the TRIDENT (HA-coated), and 32 with the DURALOC (porous coated). Of the 43 patients treated with the TRILOGY, 12 were men and 31 women, with a mean age of 59.4 years. Of the 73 patients using the TRIDENT, 35 were men and 38 women, with a mean age of 59.4 years; the 32 patients using the DURALOC included 13 men and 19 women, with a mean age of 60.0 years. There was no significant difference in the demographic data collected from the medical records and chart reviews of the three groups (Table 2).

The incidence rate of aseptic loosening after the first revision differed among the three groups, and included six cases (6/43) with the TRIDENT, 11 (11/43) with the TRILOGY, and three (3/32) with the DURALOC. The fiber-metal group had the highest loosening rate ($p=0.03$). Odds ratio analysis also showed a higher loosening rate for the fiber-metal-coated cups compared with the two other types of implants (Tables 3 and 4). Implant survival was calculated



Fig. 1. The authors' implants. (A) TRILOGY (Zimmer, Warsaw, IN, USA); (B) DURALOC (Depuy, Warsaw, IN, USA); (C) TRIDENT (Stryker, Mahwah, NJ, USA).

Table 3
Chi-square plot of loosening incidence in three groups.

Coating	Loosening	Stable	Total	Estimated
Porous	3	29	32	4.32
Fiber metal	11	32	43	5.81
HA	6	67	73	9.86
Total	20	128	148	$p = 0.038$

HA = hydroxyapatite.

Table 4
Odds ratio between groups.

	Porous	Fiber Metal	HA
Porous		3.32	0.92
Fiber metal	0.301		0.35
HA	1.08	2.86	

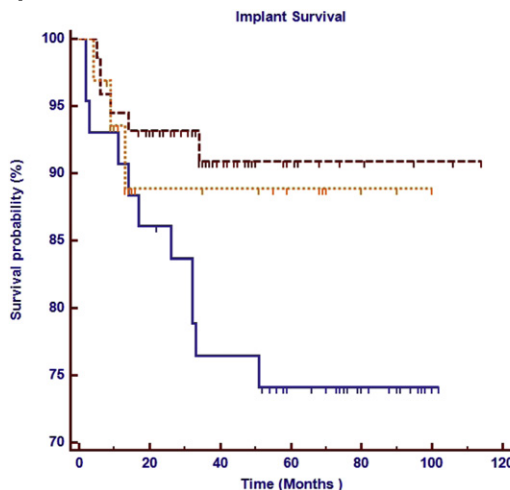
HA = hydroxyapatite.

via the Kaplan-Meier method. The HA-coated group and the porous-coated group had a similar survival curve ($p = 0.68$). Survival in the HA-coated group was superior to that in the fiber-metal group ($p = 0.03$). The porous-coated group had a better result compared with the fiber-metal group, but not to a significant extent ($p = 0.06$; Table 5).

For bone stock preservation, we measured the preoperative and implant endpoint Paprosky classification. The preoperative acetabular defects in the 3 groups were not significantly different (Table 6). The preoperative Paprosky classification was related to implant survival ($p = 0.03$; Table 7)—the higher the classification was, the shorter the survival. At the time of the next implant revision, four (4/11) patients in the fiber-metal group showed progression of the acetabular bone defect after the first revision surgery. One (1/6) patient in the HA-coated group and none in the porous group developed acetabular defect progression after revision surgery (Table 8). With regard to the high grades of acetabular defects (Paprosky 3A and 3B), there was a significantly higher loosening rate and shorter survival in the fiber-metal group (9/20) compared with the HA-coating (4/35) and porous-coating (2/14) groups (Tables 9 and 10).

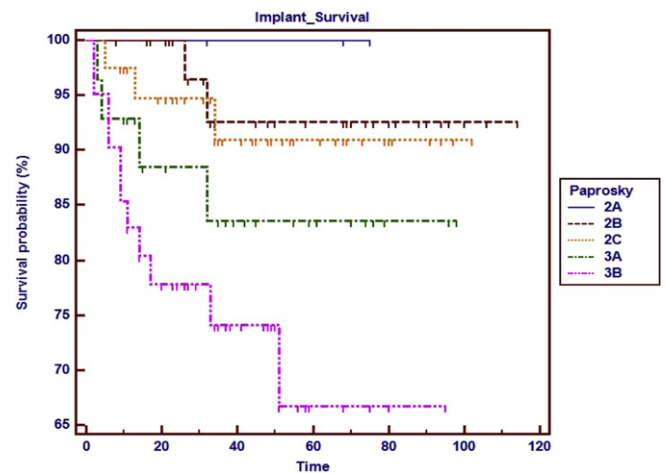
4. Discussion

There are many factors that can change the result in THA. In aseptic loosening that leads to revision, young age may be a risk

Table 5
Implant survival.**Table 6**
Pre-OP acetabular defect.

HA Coating		Porous Coating		Fiber-Metal Coating	
2A	2	2A	0	2A	1
2B	15	2B	9	2B	12
2C	21	2C	9	2C	10
3A	10	3A	9	3A	9
3B	25	3B	5	3B	11

HA = hydroxyapatite; OP = operation.

Table 7
Survival in different acetabular defects.

factor for a high revision rate.⁸ This may be due to the longer life-span of patients, which results in a greater likelihood of revision. Otherwise, no significant patient factor was reported to be related to aseptic loosening after primary hip arthroplasty or revision hip arthroplasty. In our series, age and sex did not contribute to aseptic loosening after revision hip arthroplasty.

In a literature review, HA coating was found to have good bone ingrowth and strong fixation, and the least foreign body reaction.⁹

Table 8
Acetabular defect changes in loosening implants.

Fiber-Metal Coating		Porous Coating	
Pre-OP	Post-OP	Pre-OP	Post-OP
2B	3A	2C	2C
2B	3B	3A	3A
3A	3A	3B	3B
3A	3B	HA coating	
3A	3B	Pre-OP	Post-OP
3B	3B	2C	3B
3B	3B	2C	2B
3B	3B	3B	3B
3B	3B	3B	3B
3B	3B	3B	3B
3B	3B	3B	3B

HA = hydroxyapatite; OP = operation.

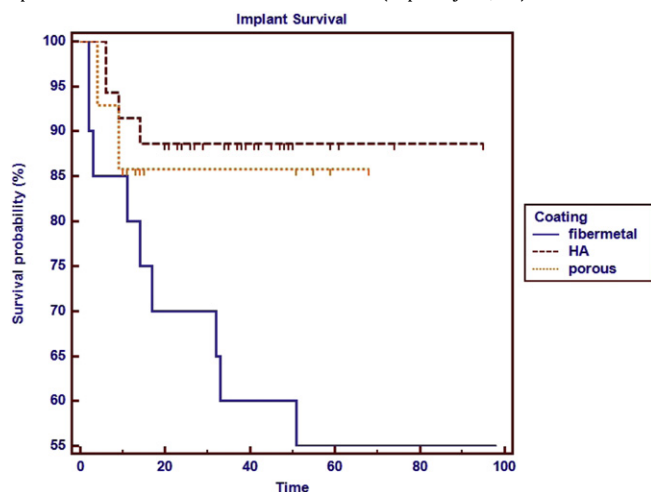
Table 9
Chi-square plot for loosening incidence in advanced acetabular defects.

Coating	Loosening	Stable	Total	Estimated
Porous	2	12	14	3.04
Fiber metal	9	11	20	4.34
HA	4	31	35	7.60
Total	15	54	69	$p = 0.029$

HA = hydroxyapatite.

Table 10

Implant survival in advanced acetabular defect (Paprosky 3A, 3B).



However, osteolysis induced by PE wearing accelerated by HA particles is a serious concern, and some investigations have shown inferior results in primary hip arthroplasty.^{10,11} Porous coating is good for bone ingrowth and high friction interference, which provides initial component stability.¹² Fiber-metal coating is also

reported to be good for bone ingrowth.¹³ However, the shedding of fiber metal has been reported, and the shedding of titanium is a risk factor for osteolysis.¹⁴ In our series, we discovered a superior result with revision cups with HA-coating and porous coating. We think good bone fixation and ingrowth are important for stability and the prevention of loosening after revision surgery. HA-induced osteolysis was not clearly found in our cases, probably due to the application of a new-generation PE. Fiber-metal coating had the highest loosening rate after revision surgery in our series, which implied that the fiber-metal-coated cup may not be appropriate for revision hip surgery (Fig. 2).

In some large series of primary THA, revision or loosening often occurred in the second decade after primary hip arthroplasty.¹⁵ However, it is unclear when aseptic loosening occurs after revision hip arthroplasty. In our series, we found a similar loosening incidence in the first 20 months after revision in the three different coating groups, but during the 20th to 59th month, implant failure developed rapidly in the fiber-metal group and implant survival dropped from 90% to 70%. During the same period, survival in the HA group and porous group was maintained at 90%. Therefore, we think the first 5 years is an important period for observation of loosening and implant survival in revision hip arthroplasty. Fiber-metal-coated cups had the shortest survival in our series.

Acetabular defect is an important factor in revision hip arthroplasty. The Paprosky classification not only describes acetabular defects, but also suggests different operative methods and results.⁵ In our series, it was reasonable that the cases with a more advanced

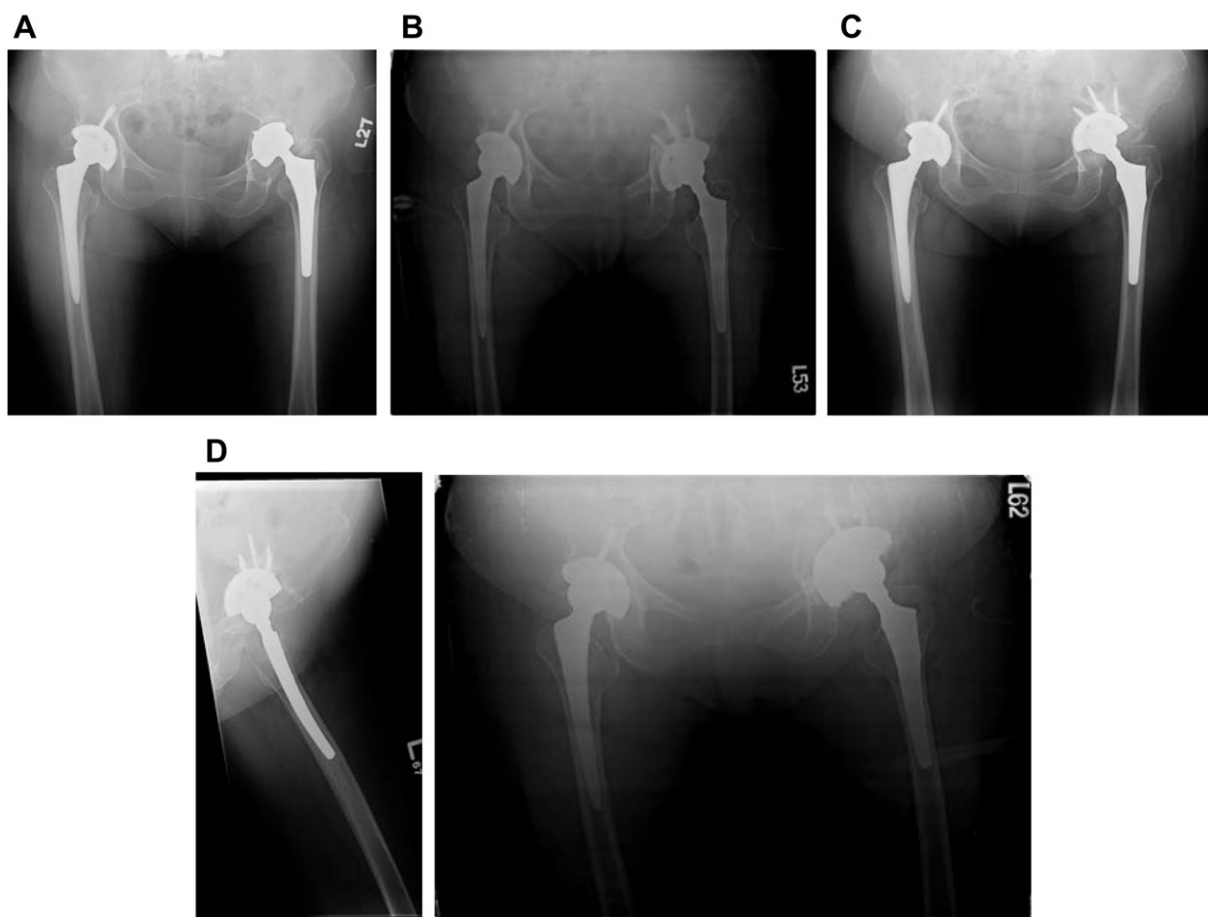


Fig. 2. A man aged 58 years with a series of revision surgeries. (A) Status post left THR with acetabulum defect; (B) revision with a fiber-metal cup; (C) 8 months later, cup loosening; (D) revision with an HA-coated cup and fixed well. HA = hydroxyapatite.

Paprosky classification had a high loosening rate and inferior survival. Among patients with a large acetabular defect of Paprosky classification 3A or 3B, we found the fiber-metal group had a very high incidence of loosening—nine in 20 cases. With regard to implant survival in cases with large bone defects, we found the fiber-metal group had a poor result, and that survival dropped to 50% in 5 years. Hence, we consider that in revision surgery with a large pre-operative acetabular bone defect, the fiber-metal-coated implant is not appropriate.

Bone stock preservation is another important issue after revision hip arthroplasty. Among the cases with loosening after revision surgery, we found the fiber-metal group had a greater likelihood of aggravating the acetabular defect (4/11) compared with the HA-group (1/6) or porous group (0/3). The fiber-metal-coated cups preserved less bone stock, and the HA- and porous-coated cups preserved more bone stock and even restoration, though without statistical significance.

5. Conclusion

Revision hip arthroplasty takes place more and more frequently and is increasingly challenging. Acetabular component coating materials are very important to implant survival in revision surgery. In our study, HA-coated and porous-coated cups both showed promising results and better bone stock restoration. Fiber-metal-coated cups were not appropriate for revision surgery, especially for large acetabular bone defects preoperatively.

References

1. S.M. Kurtz, K.L. Ong, J. Schmier, F. Mowat, K. Saleh, E. Dybvik, J. Kärrholm, et al. Future clinical and economic impact of revision total hip and knee arthroplasty. *J Bone Joint Surg Am* 89 (2007) 144–151.
2. J.C. Clohisy, G. Calvert, F. Tull, D. McDonald, W.J. Maloney. Reasons for revision hip surgery: a retrospective review. *Clin Orthop Relat Res* (2004) 188–192.
3. E.W. Morscher, A. Hefti, U. Aebi. Severe osteolysis after third-body wear due to hydroxyapatite particles from acetabular cup coating. *J Bone Joint Surg Br* 80 (1998) 267–272.
4. C.H. Geerdink, B. Grimm, W. Vencken, I.C. Heyligers, A.J. Tonino. Cross-linked compared with historical polyethylene in THA: an 8-year clinical study. *Clin Orthop Relat Res* 467 (2009) 979–984.
5. W.G. Paprosky, P.G. Perona, J.M. Lawrence. Acetabular defect classification and surgical reconstruction in revision arthroplasty. A 6-year follow-up evaluation. *J Arthroplasty* 9 (1994) 33–44.
6. I.D. Learmonth, C. Young, C. Rorabeck. The operation of the century: total hip replacement. *Lancet* 370 (2007) 1508–1519.
7. C.F. Chen, W.M. Chen, C.T. Yang, C.K. Huang, T.H. Chen. Hybrid assembly of metal head and femoral stem from different manufacturers during isolated acetabular revision. *Artif Organs* 34 (2010) E242–E245.
8. P.L. Santaguida, G.A. Hawker, P.L. Hudak, R. Glazier, N.N. Mahomed, H.J. Kreder, P.C. Coyte, et al. Patient characteristics affecting the prognosis of total hip and knee joint arthroplasty: a systematic review. *Can J Surg* 51 (2008) 428–436.
9. T. Moilanen, G.W. Stocks, M.A. Freeman, G. Scott, W.D. Goodier, S.J. Evans. Hydroxyapatite coating of an acetabular prosthesis. Effect on stability. *J Bone Joint Surg Br* 78 (1996) 200–205.
10. S. Lazarinis, J. Kärrholm, N.P. Hailer. Increased risk of revision of acetabular cups coated with hydroxyapatite. *Acta Orthop* 81 (2010) 53–59.
11. J.L. Howard, H.M. Kremers, Y.A. Loechler, C.D. Schleck, W.S. Harmsen, D.J. Berry, M.E. Cabanela, et al. Comparative survival of uncemented acetabular components following primary total hip arthroplasty. *J Bone Joint Surg Am* 93 (2011) 1597–1604.
12. B. Zicat, C.A. Engh, E. Gokcen. Patterns of osteolysis around total hip components inserted with and without cement. *J Bone Joint Surg Am* 77 (1995) 432–439.
13. G.S. Tompkins, J.J. Jacobs, L.R. Kull, A.G. Rosenberg, J.O. Galante. Primary total hip arthroplasty with a porous-coated acetabular component. Seven-to-ten-year results. *J Bone Joint Surg Am* 79 (1997) 169–176.
14. D.J. Mayman, A. González Della Valle, E. Lambert, J. Anderson, T. Wright, B. Nestor, T.P. Sculco, et al. Late fiber metal shedding of the first and second-generation Harris Galante acetabular component. A report of 5 cases. *J Arthroplasty* 22 (2007) 624–629.
15. G. Labek, M. Thaler, W. Janda, M. Agreiter, B. Stöckl. Revision rates after total joint replacement: cumulative results from worldwide joint register datasets. *J Bone Joint Surg Br* 93 (2011) 293–297.