



## Case Report

## Simple bone cyst of the talus associated with tophaceous invasion: A case report

Kun-Yi Lin<sup>a</sup>, Tsung-Ying Tsai<sup>a</sup>, Hsain-Chung Shen<sup>a</sup>, Ru-Yu Pan<sup>a</sup>, Leou-Chyr Lin<sup>a</sup>, Shyu-Jye Wang<sup>b,\*</sup><sup>a</sup> Department of Orthopedics, Tri-Service General Hospital, National Defense Medical Center, Taipei, Taiwan<sup>b</sup> Department of Orthopedics, China Medical University Hospital, Taichung, Taiwan

## ARTICLE INFO

## Article history:

Received 22 February 2011

Received in revised form

18 March 2011

Accepted 8 June 2011

Available online 22 October 2011

## Keywords:

gout

intracystic gouty tophus

simple bone cyst

talus

## ABSTRACT

Intraosseous gouty tophus is a very rare condition, and only three cases involving the talus with cystic formation have been reported in the literature. We identified a simple cystic lesion of the talus complicated by secondary intracystic gouty tophus deposition. The lesion was treated with total curettage and filled with a bony substitute of calcium sulfate pellets impregnated with autogenous bone marrow. At the 1-year follow-up, the patient demonstrated a good range of motion of the ankle joint. He was asymptomatic, and the radiographs showed total filling of the cyst with good bony union.

Copyright © 2011, Taiwan Orthopaedic Association. Published by Elsevier Taiwan LLC. All rights reserved.

## 1. Introduction

Gout is a common metabolic disorder characterized by hyperuricemia and monosodium urate crystal deposition in peripheral joints or connective tissues. Gout may present clinically as an acute attack of asymmetric polyarticular arthritis and appear radiologically similar to a solitary bone neoplasm or bone cyst. Intraosseous gouty invasion has been reported affecting the patella,<sup>1</sup> clavicle,<sup>2</sup> femoral condyle,<sup>3</sup> vertebral bodies,<sup>4</sup> and the talus.<sup>5</sup> There have been three cases reported in the literature, describing gouty invasion of the talus with the formation of a cystic lesion. Two of these cases were treated with total curettage or arthroscopic debridement; the other was treated with total curettage and filling of the cavity with calcium phosphate cement.<sup>6–8</sup> Frykberg and Noe have also described a diabetic patient with gouty invasion of the talus.<sup>9</sup> However, in this case, the patient was treated medically and was lost to follow-up.

Here, we report a case involving a 43-year-old man with a simple cystic lesion of the talus accompanied by deposition of gouty tophi in the cyst. The lesion was treated with total curettage and filled with a bony substitute of calcium sulfate pellets impregnated with autogenous bone marrow. To the best of our

knowledge, this is the first report of a simple bone cyst complicated by intracystic gouty tophus deposition.

## 2. Case report

A 43-year-old man presented for a routine physical examination in April 2008 and complained of right ankle pain for 1 month that occurred while walking. Past medical history was remarkable for gouty arthritis diagnosed 3 years earlier. He had been treated intermittently for acute gouty attacks involving the right first metatarsophalangeal joint. However, he had experienced no recent gouty attacks and was not taking medication for hyperuricemia. Treatment for his ankle pain included rest and non-steroidal anti-inflammatory agents; however, his pain persisted. The patient denied other systemic diseases, history of alcohol or drug abuse, or recent trauma.

On physical examination, the right ankle joint showed no erythema or edema. A normal gait was observed. Full range of motion (ROM) was noted at the ankle joint. Local tenderness was identified over the anteromedial aspect of the right ankle and was exacerbated with forceful inversion or dorsiflexion of the ankle. The American Orthopaedic Foot and Ankle Society (AOFAS) Clinical Rating System score (ankle–hindfoot scale) was 71 points (pain: 20; function: 41; alignment: 10).<sup>10</sup>

The patient was afebrile on presentation, and laboratory tests demonstrated a normal white blood cell count, C-reactive protein, and erythrocyte sedimentation rate. The serum uric acid level was slightly increased at 7.5 mg/dL (normal: 3.4–7.0 mg/dL). Plain radiographs of the right ankle joint showed a 27 mm × 19 mm

\* Corresponding author. Department of Orthopedics, China Medical University Hospital, No. 91, Hsueh-Shih Road, Taichung, Taiwan 40402, ROC. Tel.: +886 920 828738.

E-mail address: [tsaiort@yahoo.com.tw](mailto:tsaiort@yahoo.com.tw) (S.-J. Wang).

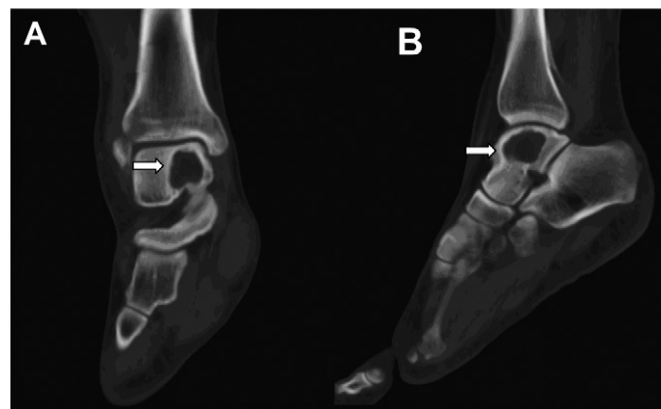
osteolytic lesion with a sclerotic margin over the posteromedial aspect of the right talus (Fig. 1). Computed tomography (CT) also confirmed the presence of a lobulated osteolytic lesion with a sclerotic rim in the same portion of the talus (Fig. 2). The absence of contrast enhancement, calcified matrix, and a fluid–fluid level on CT led to the preoperative diagnosis of an intraosseous ganglion or a simple bone cyst.<sup>11,12</sup> The diagnosis of intraosseous gouty tophus deposition was not considered before surgical intervention based on the imaging studies.

### 2.1. Surgical technique

To confirm the diagnosis of this lytic lesion, we performed intralesional excision and curettage of the bone tumor under spinal anesthesia, with an ipsilateral pneumatic thigh tourniquet to aid hemostasis. A vertical incision approximately 5 cm long was made across the anterior aspect of the ankle. The dorsalis pedis bundle and the deeper part of the anterior tibial nerve were identified between the extensor hallucis longus and extensor digitorum tendons during this anteromedial approach to the right ankle joint. The deep fascia and capsule were opened, and a cortical window (10 mm × 10 mm × 5 mm) was made at the anteromedial aspect of the talar neck near the joint cartilage over the body of the talus.

Curettage was performed, and yellowish, highly viscous mucinous material within the cyst was removed. The cystic cavity was found to be intact without subchondral defect or collapse. The lesion measured approximately 28 mm × 20 mm × 25 mm. Additionally, several calcified spots were noted in the surrounding soft tissue. Synovial biopsy and crystal analyses were carried out, and polarized microscopy confirmed the presence of negative birefringent, needle-like crystals of monosodium urate consistent with crystalline synovitis. Tophi depositions with chronic synovitis were noted in the right ankle joint.

Histological examination of the jelly-like mucinous tissue removed from the cystic lesion showed myxoid content with fibrinoid necrosis and focal, pale-pink amorphous crystals surrounded by histiocytes and foreign body giant cells (Fig. 3). Fibrotic tissue without lining epithelia and trabecular bone with focal necrosis were also identified, which confirmed the diagnosis of a simple bone cyst with secondary intracystic gouty tophus deposition. Approximately 10 mL of autogenous bone marrow harvested

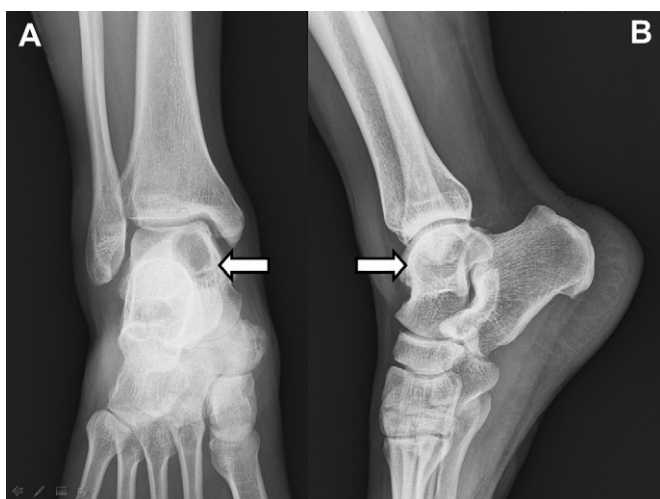


**Fig. 2.** Computed tomography of the right talus. (A) The coronal section showed a lobulated osteolytic lesion with mild sclerotic margin over the medial aspect of right talus (arrow). (B) The sagittal section showed the lytic lesion with sclerotic rims in the same area as seen in the radiographs.

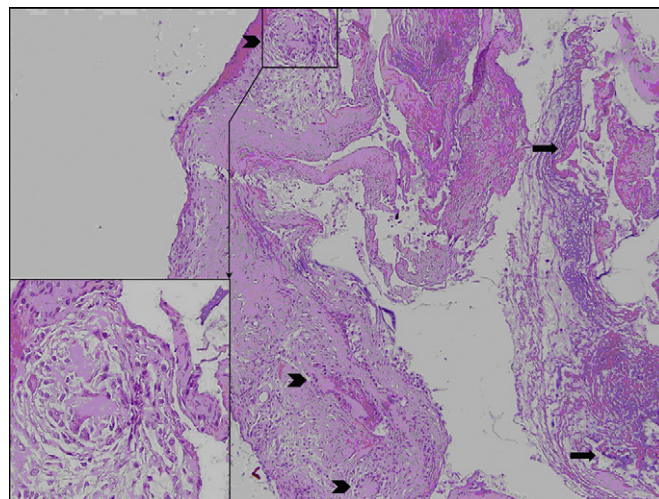
from the anterosuperior iliac spine mixed with 2 mL Osteoset bone graft substitute implantation (calcium sulfate pellets; Wright Medical Technology, Arlington, TN, USA) was packed into the cavity. The 10 mm × 10 mm × 5 mm cortical bone block was put back into its original location. The wound was closed, and a short leg splint was applied for immobilization.

### 2.2. Postoperative course

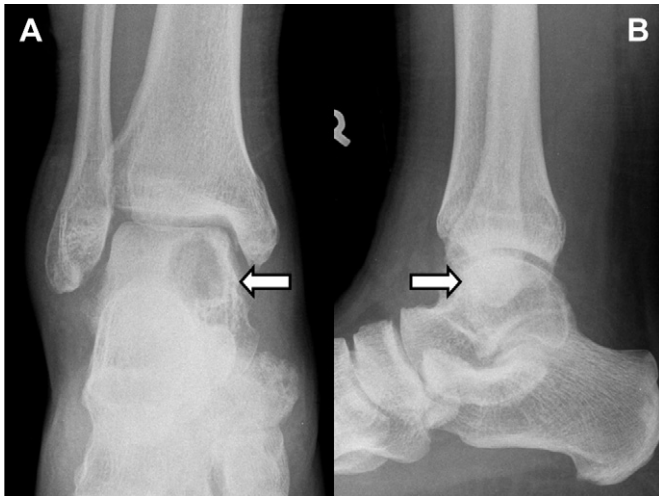Two weeks after the operation, the patient was discharged with a non-weight-bearing short-leg cast. He had no complaints of ankle pain. The cast was removed 4 weeks after surgery, and full ROM with partial weight-bearing was started. Full weight-bearing began 12 weeks after surgery. Repeat radiographs during the 2-year follow-up period showed new bone formation progressively filling in the cyst, and no signs of recurrence were noted (Fig. 4). Follow-up care during the postoperative period included dietary restrictions, as well as uricostatic and anti-inflammatory medications. The patient returned to full-time work and was asymptomatic. The



**Fig. 1.** Plain radiographs of the right talus. (A) An anteroposterior view showed a well-defined, osteolytic nodular lesion over the medial aspect of right talus (arrow). (B) A lateral view showed the presence of the oval-shaped osteolytic lesion located at the posteromedial part of the trochlea of the talus (arrow).



**Fig. 3.** Microscopic examination reveals myxoid material and fibrinoid necrosis (arrow) and focal amorphous urate crystal deposition (arrowheads) (H&E stain, 100×). The urate crystals rimmed by mononuclear macrophages and multinucleated giant cells (arrow) were also noted by high-power magnification (Intersect, H&E stain, 400×). H&E = hematoxylin and eosin.



**Fig. 4.** Lateral (A) and anteroposterior (B) views of postoperative radiograph at 1 year showed no collapse of the cystic cavity with good consolidation, no decrease of joint space or osteoarthritic change in the adjacent ankle joint.

AOFAS Clinical Rating System score was 100 (pain: 40; function: 50; alignment: 10).

### 3. Discussion

Gout is a form of chronic crystal-induced arthritis, with urate deposition occurring in subchondral bone, articular cartilage, and periarticular tissues. However, tophaceous gout occurring in the ankle, especially the talus, is rare.<sup>6</sup> In the three previous cases reported in the literature, the cystic content was removed through intralesional curettage, and chalky white material was seen.<sup>6–8</sup> However, in our case, the presence of viscous, mucinous soft tissue material was noted in the bone cyst, which is more similar to an intraosseous ganglion. As a result of the rare location and the intraoperative appearance of the lesion, the correct diagnosis was not made until the pathology report was available.

The typical radiographic features of gout include tophi, joint space preservation, asymmetric polyarticular distribution, overhanging edges of cortex, and “punched-out” erosions of bone with sclerotic borders.<sup>13</sup> A unicameral (simple) bone cyst is a common, idiopathic, benign, fluid-containing lesion. Occasionally, blood products may be found within the fluid if a previous fracture has occurred. Jaffe and Lichtenstein provided a detailed discussion of simple bone cysts in 1942.<sup>14</sup> They are well-defined, central lytic lesions that preferentially involve the tubular bones in 90–95% of patients. Within the long bones, most simple cysts are situated in the proximal metaphysis. Talus, calcaneus, and ilium involvement may also be seen in older patients.<sup>11</sup> Radiographs often show lobulated, osteolytic lesions with sclerotic rims. Calcified matrix is not visualized by CT scan, and radiographic findings are similar to an intraosseous ganglion (i.e., well-circumscribed, eccentric location of bone lysis).<sup>15</sup> Although the radiographic appearance may suggest a chondroblastoma, a giant cell tumor, or a synovial cyst, the diagnosis can be easily made through gross pathology and histological features. Both a unicameral (simple) bone cyst and an intraosseous ganglion are potential causes of the cystic bony lesion in our patient.

Although the white chalky appearance is characteristic of gouty tophus,<sup>6</sup> intraoperative gouty tophi may appear like viscous, mucinous material. The possible mechanism for the intracystic gouty tophus deposition in our case might have been from an

asymptomatic simple bone cyst within the talus, followed by secondary gouty tophi deposition causing an inflammatory reaction and subsequent ankle pain. The radiographic diagnosis would have favored a simple bone cyst; however, pathology revealed amorphous sodium urate crystals surrounded by foreign body giant cells and trabecular bone necrosis. The final diagnosis was established as a simple bone cyst involving the right talus with secondary sodium monourate crystal deposition.

According to the orthopedic literature, treatment of large cystic lesions using curettage with a bone grafting method is a standard surgical procedure.<sup>3,4</sup> Total curettage and filling the cavity with calcium phosphate cement represents another choice.<sup>8</sup> In our case, total curettage was performed along with operative harvesting of autogenous bone marrow from the ipsilateral iliac crest. Autogenous bone marrow (10 mL) was aspirated from the anterosuperior iliac spine with an 18-gauge bone marrow needle, and mixed with Osteoset bone graft substitute (2 mL calcium sulfate pellets). The mixture was packed into the cystic cavity to promote bone healing.

Bone marrow contains osteoprogenitor cells that promote bone healing and bone regeneration.<sup>16,17</sup> Autogenous bone marrow aspirated from the iliac crest is easily harvested and avoids the possible complications from harvesting autogenous bone graft (i.e., bony defects, infection, hematoma, and gait disturbance).<sup>16–18</sup> The follow-up radiographs at 1 year showed bony union with good consolidation, and no collapse of the cystic cavity or osteoarthritis of the ankle joint were observed.

Rare cases of intraosseous gouty tophus have been reported, but the present case represents the first report of a simple cystic lesion involving the talus with secondary intracystic gouty tophus deposition. Additionally, the lesion contained highly viscous mucinous soft tissue material rather than the typical chalky white material reported in the literature. Curettage and packing of the cavity with a mixture of Osteoset bone graft substitute and autogenous bone marrow were used to treat this patient. A combination of autogenous bone marrow with Osteoset bone graft substitute may enhance bone healing.<sup>18</sup> At the 1-year follow-up, our patient was asymptomatic with a good ROM at the ankle. Radiographs showed total bony filling of the cystic cavity with good bony union.

### Acknowledgments

The authors wish to thank Dr. Lin Leou-Chyr for his assistance and advice.

### References

- B.T. Cohn, J.A. Ibarra, D.W. Jackson. Erosion of the patella secondary to gout. A case report. *Am J Sports Med* 16 (1988) 421–423.
- R.C. Mahapatro, L.C. Sylvia, S.M. Becker. Case report: intraosseous gouty tophus. *J Med Soc N J* 82 (1985) 41–42.
- E. Foucar, J. Buckwalter, G.Y. El-Khoury. Gout presenting as a femoral cyst. A case report. *J Bone Joint Surg Am* 66 (1984) 294–297.
- J. Varga, C. Giampaolo, D.L. Goldenberg. Tophaceous gout of the spine in a patient with no peripheral tophi: case report and review of the literature. *Arthritis Rheum* 28 (1985) 1312–1315.
- D.B. Miskew, M.L. Goldflies. Atraumatic avascular necrosis of the talus associated with hyperuricemia. *Clin Orthop Relat Res* 148 (1980) 156–159.
- S. Raikin, B.T. Cohn. Intraosseous gouty invasion of the talus. *Foot Ankle Int* 18 (1997) 439–442.
- Y.J. Chen, R.W. Hsu, S. Hsueh. Intraosseous tophaceous pseudotumor in the trigonal process of the talus. *Clin Orthop Relat Res* 346 (1998) 190–195.
- T. Morino, M. Fujita, K. Kariyama, H. Yamakawa, T. Ogata, H. Yamamoto. Intraosseous gouty tophus of the talus, treated by total curettage and calcium phosphate cement filling: a case report. *Foot Ankle Int* 28 (2007) 126–128.
- R.G. Frykberg, B. Noe, S. Michael, E. Tierney. Intra-osseous gout in a diabetic patient. *J Foot Ankle Surg* 48 (2009) 70–73.
- H.B. Kitaoka, I.J. Alexander, R.S. Adelaar, J.A. Nunley, M.S. Myerson, M. Sanders. Clinical rating systems for the ankle-hindfoot, midfoot, hallux, and lesser toes. *Foot Ankle Int* 15 (1994) 349–353.

11. K.K. Wu. A surgically treated unicameral (solitary) bone cyst of the talus with a 15-year follow-up. *J Foot Ankle Surg* 32 (1993) 242–244.
12. P. Sarlieve, J.M. Lerais, E. Delabrousse, C. Clair, B. Kastler, D. Krause. Fluid-fluid level in an intra-osseous ganglion cyst of the talus. *J Radiol* 84 (2003) 417–419 (in French).
13. T.J. Buckley. Radiologic features of gout. *Am Fam Physician* 54 (1996) 1232–1238.
14. H.L. Jaffe, L. Lichtenstein. Solitary unicameral bone cyst with emphasis on the roentgen picture: the pathological appearance and pathogenesis. *Arch Surg* 44 (1942) 1004–1025.
15. D. Koulalis, W. Schultz. Massive intraosseous ganglion of the talus: reconstruction of the articular surface of the ankle joint. *Arthroscopy* 16 (2000) E14.
16. J.C. Leong. Percutaneous autogenous bone-marrow grafting. *J Bone Joint Surg Br* 78 (1996) 683–684.
17. N.K. Garg, S. Gaur, S. Sharma. Percutaneous autogenous bone marrow grafting in 20 cases of ununited fracture. *Acta Orthop Scand* 64 (1993) 671–672.
18. F. Lokiec, E. Ezra, O. Khernosh, S. Wientroub. Simple bone cysts treated by percutaneous autologous marrow grafting. A preliminary report. *J Bone Joint Surg Br* 78 (1996) 934–937.