

Case Report

Delayed foreign body reaction after fixation of distal radius fracture with biodegradable implant

Tsung-Ying Yang^a, Chang-Hung Huang^b, Yung-Chang Lu^{a,b}, Hsuan-Chiang Chen^b, Chun-Yen Lin^b, Chun-Hsiung Huang^{a,b,c,*}^a Department of Orthopaedic Surgery, Mackay Memorial Hospital, Taipei, Taiwan^b Department of Medical Research, Biomechanics Research Laboratory, Mackay Memorial Hospital, Taipei, Taiwan^c Mackay Medical College, Sanjhih Township, Taipei County, Taiwan

ARTICLE INFO

Article history:

Received 12 January 2011

Received in revised form

16 May 2011

Accepted 6 September 2011

Available online 19 February 2012

Keywords:

biodegradable implant

foreign body reaction

nodule

PLLA

ABSTRACT

Biodegradable implants made of polylactic acid have been used in orthopedic surgery for several decades. However, the potential complication of foreign body reaction was still reported, with varied incidence after implantation. We report a case who received open reduction and internal fixation for a distal radius fracture with a biodegradable plate and screws. A painful nodule developed at the surgical site after 18 months of implantation. The nodule was excised and histology confirmed the diagnosis of lightly eosinophilic particles of different sizes and foreign body reaction. It occurred in a non-typical location for this material. The biodegradable materials designed for fracture fixation should consider not only providing sufficient mechanical strength for the bone to heal, but also minimizing the risk of foreign body reactions as well. Further research and development for a better biodegradable material is still needed.

Copyright © 2012, Taiwan Orthopaedic Association. Published by Elsevier Taiwan LLC. All rights reserved.

1. Introduction

Biodegradable plates and screws have been used for fracture fixation in maxillofacial and orthopedic surgery for years.^{1,2} Although good fracture union has been achieved, a number of complications have emerged. Painful erythematous papule, discharge sinus, or cysts are among the most frequent complications. In the short term, this complication was regarded as benign and transient, occurring after union of the fracture, and not resulting in permanent tissue changes.³ Historically, complications are more frequent with implants made of polyglycolic acid (PGA) and occur about 2 to 4 months after implantation.³ Poly-L-lactic acid (PLLA) has a significantly lower rate of complications and takes a longer time to degrade when used as a single component.⁴ Few reports of local complications were found in the literature, especially in the distal radius. We present a case of a painful cyst which occurred 18 months after the fixation of a distal radius fracture with a biodegradable plate and screws.

2. Case report

A 50-year-old female sustained a Frykman type II fracture of the right distal radius and ulna styloid process in Jan 2008. Past medical history was negative for diabetes, ischemic heart disease, peripheral artery occlusive disease, cerebral vascular accident or renal disease. She was operated on at a different institution, where the fracture was reduced and fixed with an Inion OTPS™ biodegradable distal radius plate (Inion OTPS™, Tampere, Finland). The composition of the plate consisted of PLLA, its stereoisomer poly-D-lactic acid (PDLA) and trimethylene carbonate (TMC). The surgery was performed 4 days after the fracture. The distal radius was approached through a volar incision. The fracture was reduced anatomically and fixed with the absorbable plate and 6 screws. The screw diameters were 3.1 mm and the length ranged from 14 mm to 30 mm. The ulnar styloid process was fixed through an ulnar incision with 2 Kirschner's wires. The patient was placed in a long arm cast for 4 weeks and then a short arm cast for a further 2 weeks. Union was archived at 3 months and the patient recovered well from the procedure with good function of her right wrist.

In July 2009, a painful nodule developed over the volar aspect of the right wrist. The nodule was slightly erythematous and fluctuated, but no local edema was noted. The patient did not have fever or chills. Plain X-ray films revealed a healed fracture of the right

* Corresponding author. Department of Orthopaedic Surgery, Mackay Memorial Hospital, Number 92, Section 2, Chung-San North Road, Taipei 10449, Taiwan. Tel.: +886 2 28094661x2533; fax: +886 2 28094661x2534.

E-mail address: chhuang@ms2.mmh.org.tw (C.-H. Huang).

distal radius with remaining screw holes (Fig. 1). Ultrasonography measured a volume of $1.7 \times 0.7 \times 1.1$ cm soft tissue mass with mixed solid and cystic content.

Magnetic resonance imaging (MRI) showed a $1 \times 0.6 \times 2.2$ cm mass arising from the previous fracture site, growing in between the flexor tendon group (Fig. 2). The mass was isointense on T1 sequence, hyperintense on T2 sequence and contained some smaller particles which were hypointense on both T1 and T2. The lesion was peripherally enhanced on T1 when the contrast material is added.

Because of the painful nodule, surgery was performed in August 2009. A cystic lesion measuring $1 \times 2 \times 2$ cm in size (Fig. 3) with yellowish turbid fluid content was found. It arose from the old surgical bed connected to one of the screw holes through a fibrotic stalk. Fibrotic granulation tissues were found scattered over the surgical site. The fracture was well healed. The lesion was totally excised.

Cultures failed to reveal any microorganisms. Histology showed a pseudocyst with myxoid degeneration. Microscopic examination showed lightly eosinophilic particles of different sizes. The smaller particles were in the cytoplasm of multinucleated cells and the larger ones were located in the extracellular space surrounded by reactive cells. The overall picture was a non-specific foreign body reaction. No evidence of neoplasm or infection was seen (Fig. 4). During the latest follow-up, 4 months and 2 weeks after the excision of the cyst, a small nodule of 0.5 cm in diameter reappeared over the surgical site. However, neither pain nor erythema was noted, so no further surgery was performed.

3. Discussion

The early phase of polylactic acid degradation is chemical in nature. Biological degradation and removal of the implant occurs later. Polylactic acid can be degraded by a simple, random hydrolytic excision of the ester bonds in the polymer chain. Hydrolytic excision consists of water causing cleavage of the monomeric molecular bonds, leading to the scission of long polymer chains into

shorter chains, reducing the implant's molecular weight. This results in oligomers and monomers. As the implant loses integrity and becomes fragmented, biologic removal of the implant occurs by phagocytosis and intracellular degradation. With regard to the phagocytic and clearing capacity of the tissues, the most demanding phase is the decomposition stage, when the gross geometry of the implant is rapidly lost. At that time, the rate of production of polymeric debris may exceed the critical limits of the ability of the surrounding tissues to phagocytize and metabolize the hydrolyzed polymeric chains. The rate of degradation of PLLA implants has not been demonstrated precisely. In an animal study,⁵ high-strength PLLA rods implanted in the medullary cavity of rabbit femur, were absorbed completely by 62 months, but only partially by 42 months. The absorption rate was similar when the same rods were implanted in the subcutaneous tissue. In another study,⁶ late surgical exploration showed that PLLA plates and screws were not fully absorbed as long as 5.7 years after fixation of a zygomatic fracture. The precise timing and factors influencing PLLA degradation clearly still need further research and clarification.

PLLA is hydrophobic and crystalline, and is thus resistant to hydrolysis and degradation. The long degradation time of PLLA has led to more research to shorten the *in-vivo* material absorption time. The D stereoisomer of PLLA (PDLA) is rather amorphous and less stable, and is useful in building co-polymers. By combining PLLA and PDLA, a less crystalline and more rapidly degrading material was formed. The biodegradable materials of PLLA and PDLA have been combined in different proportions. The degradation time for the copolymer of PLLA and PDLA combined in a proportion of 96% and 4%, respectively, (P(L/D)LA 96/4) is about 2 years.⁷ The degradation time for P(L/D)LA 70/30, is 2–3 years.^{8,9} The addition of PDLA to PLLA effectively reduces the degradation time of the copolymer.

According to the manufacturer's official data, Inion OTPS Biodegradable Distal Radius Plates (Inion, Tampere, Finland) gradually lose their strength during the first 18–36 weeks after implantation. Complete resorption takes place between 2 and 4 years. Mavrogenis et al reported the use of implants of the same

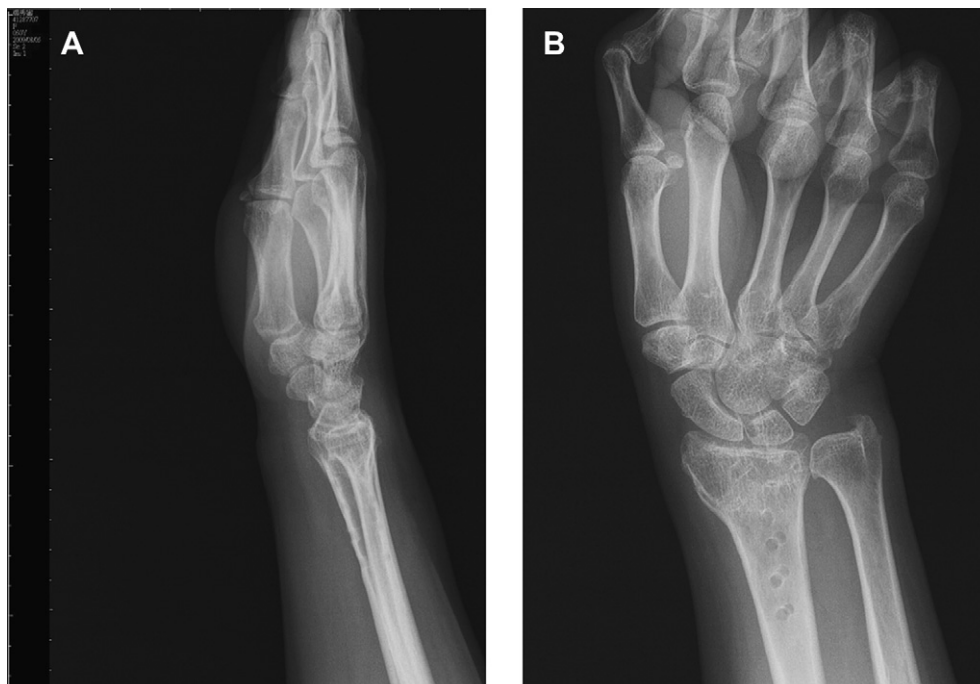


Fig. 1. (A) Anteroposterior and (B) lateral views of the right wrist showing a healed distal radius fracture with remaining screw holes.

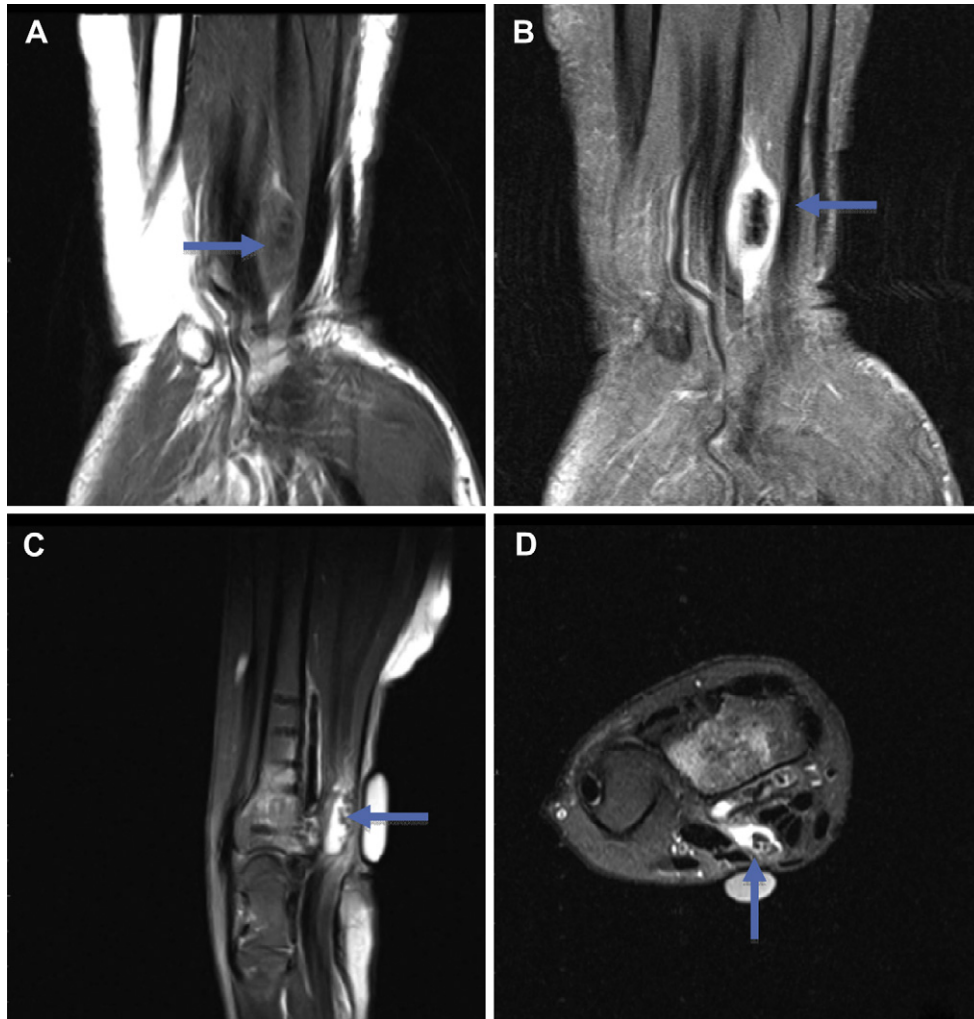


Fig. 2. MRI of the right wrist showed a soft tissue mass (arrow) on T1 coronal view (A) and T1 contrasted coronal view (B). T2 sequence MRI on sagittal and transverse plane showing a high signal cystic lesion with some debris inside growing out from the previous surgical site (arrows) (C, D).

material in three pediatric patients with distal radius fractures.¹⁰ No foreign body reaction was noted after 18 to 22 months of follow-up. Givissis et al reported a series of ten patients with metacarpal fracture fixed with OTPS plates and screws. Among them, four patients required debridement and implant removal for foreign body reactions.¹¹ The excised material consisted of reactive

tissue with fluid accumulation and solid remnant of the plate and screws. No definite cystic formation was described. The time from implantation to the onset of symptoms was between 14 and 19 months. Kukk and Nurmi reported the occurrence of subcutaneous soft tissue reactions in patients treated with OTPS plates and screws for ankle fractures.¹² The incidence of soft tissue reaction was 8% in

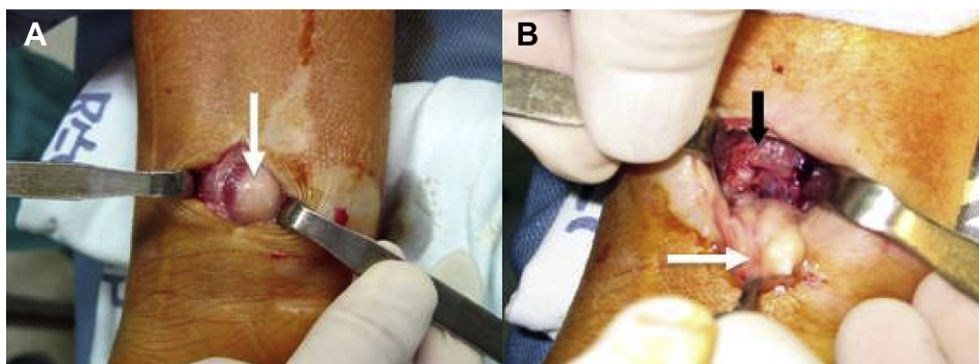


Fig. 3. Intraoperative photographs of the (A) cyst (white arrow) located between the wrist flexor tendons and (B) granulomatous tissues (black arrow) deep to the cyst (white arrow) seen once the cyst had been elevated.

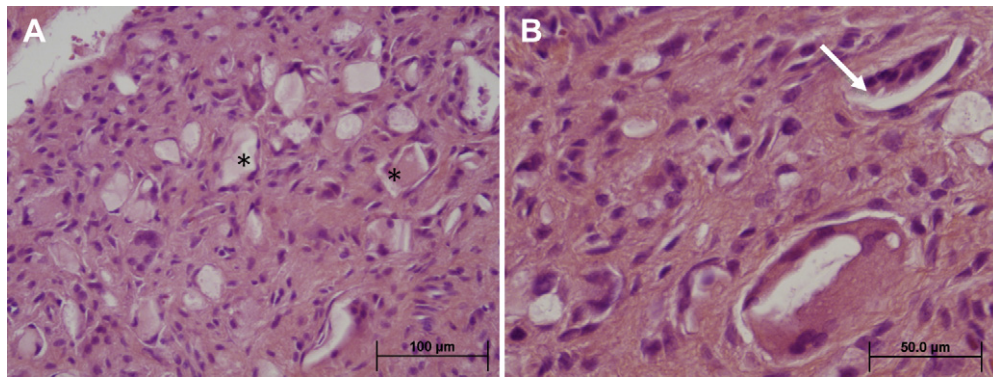


Fig. 4. Histological examination of the excised cyst. Multiple eosinophilic particles located both (A) extracellularly (*) and (B) intracellularly (arrow). Numerous multinucleated giant cells are present. Scale bar (a) 100 μm , (b) 50 μm .

their series. The excised tissue consisted of materials similar to sour milk and undegraded screw heads, without a definite pseudocyst formation. The time elapsed from implantation to the onset of the symptoms was from 8 to 18 months. In our case, on the contrary, there was a pseudocyst containing aseptic fluid in addition to reactive tissues surrounding the cyst. Most of the reports concerning complications with biodegradable materials occur in the locations with poor vascularization.^{1,13} It is theorized that decreased vascularity and high implant volume are possible risk factors for foreign body reactions. In our case, the distal radius is regarded as a highly vascularized area, thus should be less prone to foreign body reactions. However, in this case, a T shaped plate and 6 screws were used, which had a larger volume compared to rods and screws used in reported cases of complications. This may predispose to foreign body reaction.

A small painless nodule appeared on the surgical site at the latest follow-up. No further surgery was performed, due to its asymptomatic nature, so no tissue diagnosis was available. We suspect that the nodule was the result of fluid accumulation due to the reaction to the residual implant which was not totally cleared during the excision. Wider excision including intraosseous screws removal might help to avoid the recurrence of the nodule.

The perfect material for biodegradable implants has not been developed yet. The optimal material should be strong enough to provide the necessary mechanical rigidity for fixation. It should remain in place, keeping its strength long enough for the bone to heal, usually at least 6 months. The implant should be gradually absorbed within 1 to 2 years. Finally, after the material is disintegrated, the particles should be small enough to facilitate phagocytosis.

Contemporary biodegradable implants provide the potential advantage of avoiding a second surgery for implant removal. Unfortunately, we encountered a specific case requiring an additional surgery to manage a painful nodule on the surgical site after 18 months of implantation. The best way to provide sufficient

mechanical strength with an appropriate matched degradation time in the contemporary biodegradable materials, is still a challenging issue. Modification of the optimal material composition is required to minimize complications.

References

1. C.G. Ambrose, T.O. Clanton. Bioabsorbable implants: review of clinical experience in orthopedic surgery. *Ann Biomed Eng* 32 (2004) 171–177.
2. W.J. Ciccone, C. Motz, C. Bentley, J.P. Tasto. Bioabsorbable implants in orthopaedics: new developments and clinical applications. *J Am Acad Orthop Surg* 9 (2001) 280–288.
3. O. Böstman, E. Hirvensalo, J. Makinen, P. Rokkanen. Foreign body reactions to fracture fixation implants of biodegradable synthetic polymers. *J Bone Joint Surg Br* 72 (1990) 592–596.
4. G.M. Kontakis, J.E. Pakgalos, T.I. Tosoudinis, J. Melissas, P. Katonis. Bioabsorbable materials in orthopaedics. *Acta Orthop Belg* 73 (2007) 159–169.
5. Y. Matsusue, S. Hanafusa, T. Yamamuro, Y. Shikunami. Tissue reaction of bioabsorbable ultra high strength poly L-lactide rod. A long-term study in rabbits. *Clin Orthop Relat Res* 317 (1995) 246–253.
6. J.E. Bergsma, W.C. de Bruijn, F.R. Rozema, R.R.M. Bos, G. Boering. Late degradation tissue response to poly(L-lactide) bone plates and screws. *Biomaterials* 16 (1995) 25–31.
7. H.H. Peltoniemi, R.M. Tulamo, T. Toivonen, D. Hallikainen, P. Törmälä, T. Waris. Biodegradable semirigid plate and miniscrew fixation compared with rigid titanium fixation in experimental calvarial osteotomy. *J Neurosurg* 90 (1999) 910–917.
8. Y.H. An, S.K. Woolf, R.J. Friedman. Pre-clinical in vivo evaluation of orthopaedic bioabsorbable devices. *Biomaterials* 21 (2000) 2635–2652.
9. N. Ashammakhi, R. Suuronen, J. Tiainen, P. Törmälä, T. Waris. Spotlight on naturally absorbable osteofixation devices. *J Craniofac Surg* 14 (2003) 247–259.
10. A.F. Mavrogenis, A.D. Kanellopoulos, G.N. Nomikos, P.J. Papagelopoulos, P.N. Soucacos. Early experience with biodegradable implants in pediatric patients. *Clin Orthop Relat Res* 467 (2009) 1591–1598.
11. P.K. Givissis, S.I. Stavridis, P.J. Papagelopoulos, P.D. Antonarakos, A.G. Christodoulou. Delayed foreign-body reaction to absorbable implants in metacarpal fracture treatment. *Clin Orthop Relat Res* 468 (2010) 3377–3383.
12. A. Kukkk, J.T. Nurmi. A retrospective follow-up of ankle fracture patients treated with a biodegradable plate and screws. *Foot Ankle Surg* 15 (2009) 192–197.
13. O. Böstman, H. Pihlajamäki. Adverse tissue reactions to bioabsorbable fixation devices. *Clin Orthop Relat Res* 371 (2000) 216–227.