



Original Article

Deformities of proximal femur in spastic hip displacement: A reconstructed three-dimensional computed tomography model approach

Ying-Chih Wang, Wei-Chun Li, Hsuan-Kai Kao, Wen-E Yang, Chia-Hsieh Chang*

Department of Orthopedic Surgery, Chang Gung Memorial Hospital, Chang Gung University, Taoyuan, Taiwan

ARTICLE INFO

Article history:

Received 4 December 2012

Received in revised form

11 January 2013

Accepted 6 February 2013

Available online 10 May 2013

Keywords:

cerebral palsy

femoral deformity

spastic hip

ABSTRACT

Background/Purpose: Spastic hip displacement is a common musculoskeletal problem in cerebral palsy (CP), leading to further complications in daily life. Deformities of the proximal femur were regarded as a factor in hip displacement, and therefore, femoral osteotomy is often recommended. This study aims to identify the relationship between hip displacement and femoral deformities.

Methods: We retrospectively collected preoperative radiography and three-dimensional computed tomography (3D-CT) images from 19 nonambulatory CP children with unilateral hip displacement (average age: 8.4 years; range: 4.4–13.6). The 3D image of femur was reconstructed for measuring the femur anteversion angle (FAA) and true femoral neck-shaft angle (NSA). The association among migration percentage (MP), acetabular index (AI), FAA, and NSA between nondisplaced and displaced hips was analyzed by paired *t* test and its correlations were identified.

Results: The FAA and AI are significantly greater in displaced hips (42.7° vs. 36.3° and 32.8° vs. 22.7°, respectively, $p < 0.001$). However, the NSA is similar between displaced and nondisplaced hips. The AI and FAA have significantly positive correlations with MP between nondisplaced hips and displaced hips (0.69 and 0.57, respectively).

Conclusion: Using reconstructed 3D-CT images we can directly measure and prove these femoral deformities. We found that AI has a positive correlation with MP (0.69), which is consistent with the results of previous studies. The displaced side has greater femur anteversion (42.7° vs. 36.3°), and coxa valga is common in these nonambulatory patients, irrespective of whether or not these patients underwent hip displacement. In addition, the severity of AI and anteversion angle will be affected by the MP.

Copyright © 2013, Taiwan Orthopaedic Association. Published by Elsevier Taiwan LLC. All rights reserved.

1. Introduction

Cerebral palsy (CP) is a static encephalopathy affecting posture and motor function by a variety of neurological disorders. As a consequence, hip displacement is the most common musculoskeletal problem in CP.¹ The incidence of hip displacement is correlated to the severity of motor impairment. Based on the gross motor function classification system (GMFCS),^{2,3} hip displacement is seldom seen in the highest function level I patients and would occur in 89% of the lowest function level V patients.² The development of hip displacement would further have a negative impact on the pre-existing motor disability.^{4,5}

Following spastic hip displacement, the changes over the pelvic acetabulum are global dysplasia with the anterior aspect being the most affected. With the progress of hip displacement, the direction of displacement and acetabular deficiency transfers to the posterolateral aspect as the hip becomes dislocated.⁶ Besides, deformities of the proximal femur, including coxa valga and excessive anteversion, are also responsible for hip displacement.^{2,7–9} Robin et al reported that anteversion and neck-shaft angle (NSA) of the femur increased stepwise with the GMFCS level.⁷

Coxa valga is represented by NSA of the femur. The NSA is measured on the anteroposterior radiograph of the pelvis.^{7,10} However, the measure is liable to be affected by the axial rotational of the femur, and malrotation of the femur is commonly seen in nonambulatory CP patients.⁷ Regarding femur anteversion, the traditional measure is to use Charles' method by taking hip anteroposterior radiograph with the hip and knee flexed at 90° and measuring the axis of the neck and the transcondylar plane.¹¹ However, it is not validated in clinical use. Therefore, several methods have been reported to measure femoral anteversion, such

* Corresponding author. Department of Orthopedic Surgery, Chang Gung Memorial Hospital, Linkou and Keelung, 5 Fusing Street, 333, Kwei-Shan, Taoyuan 33305, Taiwan. Tel.: +886 3 3281200x2423; fax: +886 3 3278113.

E-mail address: chiahsiehchang@gmail.com (C.-H. Chang).

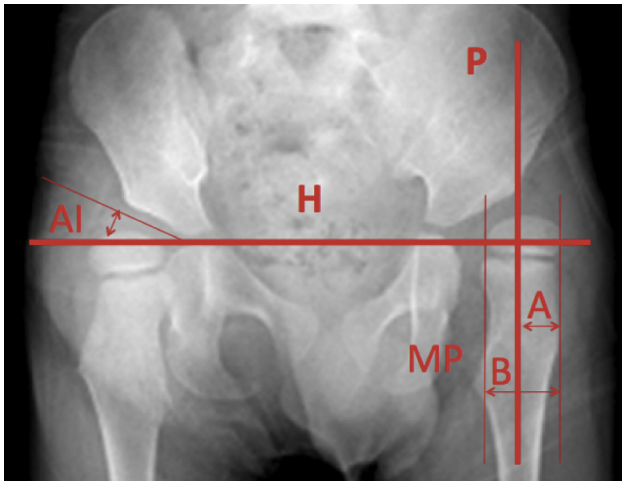


Fig. 1. Measurement of migration percentage (MP) and acetabular index (AI). H = Hilgenreiner's horizontal line between triradiate cartilages. P = Perkin's line drawn perpendicular to the H line at the lateral margin of the acetabulum. The MP represents that portion of the ossified femoral head that has migrated laterally beyond Perkin's line. $MP = A/B \times 100\%$. The AI is measured in degrees.

as trochanteric prominence angle test,^{9,12} ultrasonography,^{13,14} two-dimensional computed tomography,^{15,16} three-dimensional computed tomography (3D-CT),^{17–19} and magnetic resonance imaging.²⁰ Chung et al suggested that computed tomographic examination can probably be replaced by physical examination and plain radiograph for ambulatory CP patients with stable hips.⁸ However, hip displacement occurs predominantly in GMFCS IV and V non-ambulatory patients.

It is a dilemma that clinical measurements of femur anteversion and coxa valga are often confounded by soft-tissue contracture and profound bone deformity, whereas contracture and deformity are common problems in low-function CP patients, who are the

population most liable to hip displacement. With the advancement in image technique, structure of the femur could be reconstructed and realigned to a neutral position. This study uses reconstructed 3D-CT to assess femoral deformities. We aim to identify the relationship between femoral deformities and hip displacement in a group of nonambulatory CP patients who had unilateral hip dislocation.

2. Materials and methods

We retrospectively collected preoperative images from 19 consecutive cases of nonambulatory CP patients who underwent orthopedic surgery for unilateral hip displacement in our institution from January 2008 to January 2012. Their age ranged from 4.4 to 13.6 years (mean: 8.4 years). No surgery had been performed at the lower extremities or pelvis before. They had received complete preoperative assessment and left radiographs and 3D-CT data in the authors' hospital. The collection and analysis of their radiographic data from image database were approved by the Institutional Review Board.

The radiographic parameters are acetabular index (AI), migration percentage (MP), femur anteversion angle (FAA), and femoral NSA. The AI and MP values are obtained from anteroposterior radiograph of pelvis. The AI is the angle between the Hilgenreiner line and a line drawn from the triradiate cartilage to the lateral edge of the acetabulum. The MP represents that portion of ossified femoral head that has migrated laterally beyond the Perkin's line (Fig. 1).²¹

The FAA and NSA were assessed by reconstructed 3D-CT images. The 3D image of femur was reconstructed and realigned by a standard coronal plane that was defined by posterior femoral condyles and greater trochanter. The FAA is the angle formed by a line drawn from center of the femoral head to the midpoint of greater trochanter and a line tangential to the two posterior femoral condyles, when the femur is viewed along the longitudinal axis from proximal to distal above. The NSA is the angle between

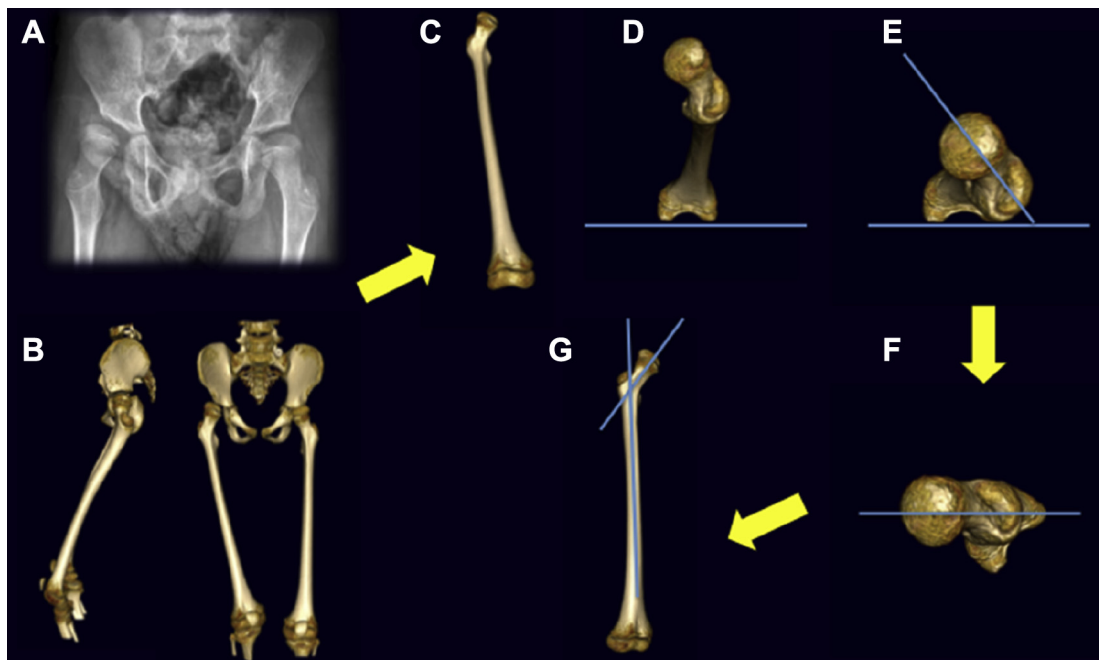


Fig. 2. (A) Plain anteroposterior radiograph of pelvis. (B) Reconstructed three-dimensional computed tomography imaging of the pelvis and femur (including knee). (C) Isolate one femur. (D) Use posterior femoral condyle as a guideline. (E) Measurement of femoral anteversion angle. (F) A perpendicular line drawn through the midpoint of the femoral neck and the center of the femoral head. (G) Measurement of the neck-shaft angle.

longitudinal axis of femoral shaft and the axial line of femoral neck. The true NSA is measured when the femur is rotated internally until the neck axis is parallel to the coronal plane. The influence of femur anteversion on the measure of NSA could be eliminated by this method (Fig. 2).

The association between femur deformities and hip displacement is assessed by comparing FAA and NSA between displaced hips and nondisplaced hips using paired *t* test. Correlations among MP and the other three parameters, AI, FAA, and NSA, were analyzed by Pearson *r* to elucidate the relationship between hip displacement and bony deformities.

3. Results

Radiographic data including plain radiograph and reconstructed 3D-CT images were obtained from the 19 nonambulatory CP children. Eight children have displaced hip in the left side and 11 children in the right side. Seven children are GMFCS IV and 12 children are GMFCS V (Table 1).

Plain radiograph images of the pelvis showed that the MP and AI are significantly greater in displaced hips than nondisplaced hips (64.6° vs. 31.0° and 32.8° vs. 22.7°, respectively, both *p* < 0.001). The AI data are significantly correlated to the MP data (*r* = 0.69, *p* < 0.05). From reconstructed 3D-CT images, the FAA was found to be significantly greater in displaced hips than nondisplaced hips (42.7° vs. 36.3°, *p* < 0.001). However, there is no difference in NSA between displaced and nondisplaced hips, although the NSA data in these low-function-level patients are higher than that in normal population. The FAA data have significantly positive correlation with the MP data in the 38 hips of 19 patients (*r* = 0.57, *p* < 0.05) (Table 2).

4. Discussion

These hips are normal at birth in children with CP. However, bone deformity and hip displacement develop gradually following lack of ambulation and postural asymmetry.¹⁵ Previous reports about incidence of hip displacement varied from 2% and 75%,^{22–24} and the incidence is directly related to gross motor function level and the involvement of CP.² Besides the hip displacement, femur anteversion and coxa valga are also related to gross motor function

Table 1
General data of the 19 cerebral palsy children analyzed in the study.

Patient no.	Gender	Age (y)	Displaced side	Displaced side MP (%)	Nondisplaced side MP (%)	GMFCS
1	Female	10.0	Left	94	19	V
2	Female	5.7	Right	79	20	V
3	Female	9.6	Right	66	27	V
4	Female	5.1	Right	68	33	V
5	Female	4.4	Left	59	25	IV
6	Female	5.4	Right	55	31	IV
7	Female	13.6	Left	74	41	V
8	Male	4.2	Right	89	33	V
9	Male	13.5	Left	34	22	IV
10	Female	12.9	Right	84	32	V
11	Female	8.2	Left	45	22	IV
12	Male	8.3	Right	54	36	V
13	Female	12.6	Right	62	26	V
14	Female	7.4	Left	53	40	V
15	Female	4.2	Right	76	36	V
16	Male	8.1	Right	50	27	IV
17	Male	9.7	Left	64	39	IV
18	Male	12.5	Left	62	35	V
19	Female	4.4	Right	59	44	IV

GMFCS = gross motor function classification system; MP = migration percentage; y = years.

Table 2
Comparison of radiographic parameters between nondisplaced hips and displaced hips (*n* = 19).

Characters of CP hips	Migration percentage	Acetabular index	Anteversion angle	Neck-shaft angle
Nondisplaced hips	31.0% (19–41)	22.7° (18–44)	36.3° (21–49)	144.1° (130–165)
Displaced hips	64.6% (34–94)	32.8° (21–39)	42.7° (29–60)	142.9° (128–155)
	<i>p</i> < 0.001*	<i>p</i> < 0.001*	<i>p</i> = 0.005*	<i>p</i> = 0.354*
Pearson <i>r</i>	—	0.69**	0.57**	−0.02

* Comparison between nondisplaced hips and displaced hips.

** Significant correlation with migration percentage.

CP = cerebral palsy.

level.⁷ The motor function, disease severity, bone deformity, and hip displacement are correlated among each other.

This study uses reconstructed 3D-CT images to prevent the confounding from posture in measuring bone alignment. The data confirm excessive anteversion of proximal femur in CP children and the degree of anteversion is associated with hip displacement. Coxa valga was believed to be responsible for spastic hip displacement, but the NSA data revealed in this study are not associated with hip displacement.

When comparing the study data with that reported in literature, the mean of FAA in GMFCS level IV or V children is 40° in Robin and co-workers' report.⁷ The data are similar to the 42.7° of displaced hips in our patients (compare Robin and co-workers' NSA data in IV and V patients). However, there are no significant differences in femoral NSA between displaced and nondisplaced hips. We could conclude that coxa valga is a common problem in nonambulatory CP patients, irrespective of whether they had hip displacement or not.

Although our study is conducted using a small sample size of nonambulatory children with CP, the bone structure of the femur could only be measured exactly after its realignment to a standard neutral position. The study results do not support the relationship between coxa valga and hip displacement. Nevertheless, varus osteotomy of the proximal femur is still a necessary surgical procedure to reduce a dislocated hip and maintain a good long-term result in spastic CP patients.

In conclusion, hip displacement in patients with CP is significantly associated with increased femur anteversion, but not coxa valga. Our results confirm that femoral anteversion in displaced hip is greater than that in nondisplaced hips and significantly correlated to degree of displacement. Although the causal relationship between anteversion and hip displacement requires further study, the preliminary data represent the exact changes of proximal femur in CP children.

References

1. F. Standley, E. Blair, E. Alberman. Cerebral palsies: epidemiology and causal pathways. In: Clinics in Developmental Medicine, Mac-Keith Press, London; 2000. p. 151.
2. B. Soo, J.J. Howard, R.N. Boyd, S.M. Reid, A. Lanigan, R. Wolfe, D. Reddihough, et al. Hip displacement in cerebral palsy. *J Bone Joint Surg Am* 88 (2006) 121–129.
3. R. Palisano, P. Rosenbaum, S. Walter, D. Russell, E. Wood, B. Galuppi. Development and reliability of a system to classify gross motor function in children with cerebral palsy. *Dev Med Child Neurol* 39 (1997) 214–223.
4. D.R. Cooperman, E. Bartucci, E. Dietrick, E.A. Millar. Hip dislocation in spastic cerebral palsy: long-term consequences. *J Pediatr Orthop* 7 (1987) 268–276.
5. W.A. Herndon, L. Bolano, J.A. Sullivan. Hip stabilization in severely involved cerebral palsy patients. *J Pediatr Orthop* 12 (1992) 68–73.
6. C.H. Chang, K.N. Kuo, C.J. Wang, Y.Y. Chen, H.Y. Cheng, H.K. Kao. Acetabular deficiency in spastic hip subluxation. *J Pediatr Orthop* 31 (2011) 648–654.
7. J. Robin, H.K. Graham, P. Selber, F. Dobson, K. Smith, R. Baker. Proximal femoral geometry in cerebral palsy: a population-based cross-sectional study. *J Bone Joint Surg Br* 90 (2008) 1372–1379.

8. C.Y. Chung, K.M. Lee, M.S. Park, S.H. Lee, I.H. Choi, T.J. Cho. Validity and reliability of measuring femoral anteversion and neck-shaft angle in patients with cerebral palsy. *J Bone Joint Surg Am* 92 (2010) 1195–1205.
9. P.A. Ruwe, J.R. Gage, M.B. Ozonoff, P.A. DeLuca. Clinical determination of femoral anteversion. A comparison with established techniques. *J Bone Joint Surg Am* 74 (1992) 820–830.
10. R.M. Kay, K.A. Jaki, D.L. Skaggs. The effect of femoral rotation on the projected femoral neck-shaft angle. *J Pediatr Orthop* 20 (2000) 736–739.
11. C.T. Ryder, L. Crane. Measuring femoral anteversion; the problem and a method. *J Bone Joint Surg Am* 35 (1953) 321–328.
12. J.R. Davids, P. Benfanti, D.W. Blackhurst, B.L. Allen. Assessment of femoral anteversion in children with cerebral palsy: accuracy of the trochanteric prominence angle test. *J Pediatr Orthop* 22 (2002) 173–178.
13. L. Berman, R. Mitchell, D. Katz. Ultrasound assessment of femoral anteversion. A comparison with computerised tomography. *J Bone Joint Surg Br* 69 (1987) 268–270.
14. G.S. Lausten, F. Jørgensen, J. Boesen. Measurement of anteversion of the femoral neck. Ultrasound and computerised tomography compared. *J Bone Joint Surg Br* 71 (1989) 237–239.
15. N. Sugano, P.C. Noble, E. Kamaric. A comparison of alternative methods of measuring femoral anteversion. *J Comput Assist Tomogr* 22 (1998) 610–614.
16. D.S. Weiner, A.J. Cook, W.A. Hoyt Jr., C.E. Oravec. Computed tomography in the measurement of femoral anteversion. *Orthopedics* 1 (1978) 299–306.
17. J.S. Kim, T.S. Park, S.B. Park, J.S. Kim, I.Y. Kim, S.I. Kim. Measurement of femoral neck anteversion in 3D. Part 1: 3D imaging method. *Med Biol Eng Comput* 38 (2000) 603–609.
18. M.F. Abel, D.H. Sutherland, D.R. Wenger, S.J. Mubarak. Evaluation of CT scans and 3-D reformatted images for quantitative assessment of the hip. *J Pediatr Orthop* 14 (1994) 48–53.
19. R.J. Tomczak, K.P. Guenther, A. Rieber, P. Mergo, P.R. Ros, H.J. Brambs. MR imaging measurement of the femoral antetorsional angle as a new technique: comparison with CT in children and adults. *AJR Am J Roentgenol* 168 (1997) 791–794.
20. J.R. Davids, A.D. Marshall, E.R. Blocker, S.L. Frick, D.W. Blackhurst, E. Skewes. Femoral anteversion in children with cerebral palsy. Assessment with two and three-dimensional computed tomography scans. *J Bone Joint Surg Am* 85-A (2003) 481–488.
21. J. Parrott, R.N. Boyd, F. Dobson, A. Lancaster, S. Love, J. Oates, R. Wolfe, et al. Hip displacement in spastic cerebral palsy: repeatability of radiologic measurement. *J Pediatr Orthop* 22 (2002) 660–667.
22. M.R. Bagg, J. Farber, F. Miller. Long-term follow-up of hip subluxation in cerebral palsy patients. *J Pediatr Orthop* 13 (1993) 32–36.
23. G. Häggglund, H. Lauge-Pedersen, P. Wagner. Characteristics of children with hip displacement in cerebral palsy. *BMC Musculoskelet Disord* 8 (2007) 101–107.
24. R.K. Beals. Developmental changes in the femur and acetabulum in spastic paraplegia and diplegia. *Dev Med Child Neurol* 11 (1969) 303–313.