

Case Report

The clinical significance of rapid prototyping technique in complex spinal deformity surgery—Case sharing and literature review



Zhou-Liang Song, Chi-Kuang Feng*, Fang-Yao Chiu, Chien-Lin Liu

Department of Orthopaedics and Traumatology, Taipei Veterans General Hospital, Taipei, Taiwan

ARTICLE INFO

Article history:

Received 27 October 2012

Received in revised form

14 January 2013

Accepted 22 April 2013

Available online 23 August 2013

Keywords:

3D images

rapid prototyping

spinal deformities

surgical planning

ABSTRACT

Treatment of complex severe spinal deformities, such as scoliosis with a Cobb angle greater than 90°, critical spinal kyphosis, or vertebral and rib deformity with impaired lung capacity, remains a great challenge. Preoperative image studies including plain film radiography, computed tomography, and magnetic resonance imaging provide only two-dimensional (2D) images and limited information about these severe deformities. In addition, these studies cannot directly offer visual or tactile feedback for surgeons and patients. On the contrary, the rapid prototyping (RP) technique provides surgeons with full-scale, 3D models, which make more accurate and more direct morphometric information of the complex spinal deformity obtainable. In this study, we intend to share our experience with the RP technique in pediatric spine deformity cases and to provide a literature review. In our study, two patients with severe spinal deformity were included. A real-size spinal model was produced for each patient on the basis of contiguous computer tomography with a slice thickness of 1 mm. All models were used to plan the resection and to identify the anatomic landmarks during the operation. With the aid of these full-scale spinal models, all surgical procedures were performed exactly according to the preoperative plan. A 16-year-old girl with congenital scoliosis with a Cobb angle greater than 90° received staged surgery, including vertebral column resection, correction, and posteriolateral spinal fusion. The other patient was a 3-year-old boy with 80° of Gibbus spine deformity. By means of an anteriolateral approach after thoracotomy, the paraspinal abscess debridement, vertebral column resection, and vertical expandable prosthetic titanium rib application were performed. No postoperative complications such as spinal cord, nerve root, or major vascular injuries were found. The 3D RP models are really helpful in providing direct visual and tactile feedback, improving preoperative planning, identifying the important anatomic landmarks during the surgery, and communicating with patients. If the RP technique can be improved in the future, it is likely to become more acceptable and practical.

Copyright © 2013, Taiwan Orthopaedic Association. Published by Elsevier Taiwan LLC. All rights reserved.

1. Introduction

Treatment of complex severe spinal deformities, such as scoliosis with a Cobb angle of more than 90°, critical spinal kyphosis, vertebral and rib deformity with impaired lung capacity, remains a great challenge. Because of these kinds of severe deformities, we often confront unexpected malformations that are discovered during operations, which leads to higher operative

risks of major neurologic damage, vascular injury, and other complications.^{1,2} Preoperative image studies including plain film radiography, computed tomography (CT), and magnetic resonance imaging (MRI) provide only two-dimensional (2D) images and limited information about these severe deformities. They cannot directly offer visual and tactile feedback for surgeons and patients. Even though 3D CT imaging allows construction of a virtual anatomic overview,^{3,4} the 3D model still uses 2D prints.⁵ It does not provide tactile feedback and cannot be used directly on the operating table.

Rapid prototyping (RP), which was developed in the 1980s, is a manufacturing technique that accurately reconstructs 3D physical objects from computed tomographic image file data. The application of spinal biomodeling was first described by D'Urso et al⁶ in

* Corresponding author. Department of Orthopaedics and Traumatology, Taipei Veterans General Hospital, Number 201, Section 2, Shih-Pai Road, Beitou District, Taipei City, Taiwan. Tel.: +886 2 8757557.

E-mail address: ckfeng@vghtpe.gov.tw (C.-K. Feng).

1999. A subsequent study of six patients in 2001 concluded that real-size spinal models provided an excellent understanding of complex spinal pathologies and assisted pre- and perioperative planning and performance.⁷ Some studies were conducted by using these RP models to facilitate spinal instrumentation⁸ and give surgeons more accurate morphometric information to increase the accuracy of insertion of pedicle screws.⁹

In this study, we provide the first report of RP usage and surgical planning of complex severe spinal deformity in Taiwan. Our aim was to demonstrate the application of the RP model and to

recommend a technical aid to preoperative planning, intraoperative anatomic identification, and communication with patients.

2. Case report

The first case was a 16-year-old girl suffering from neuromuscular scoliosis due to neurofibromatosis type 1. Her preoperative scoliosis Cobb angle was more than 100° (as shown in the spine anteroposterior X-ray), combined with a kyphotic angle of more

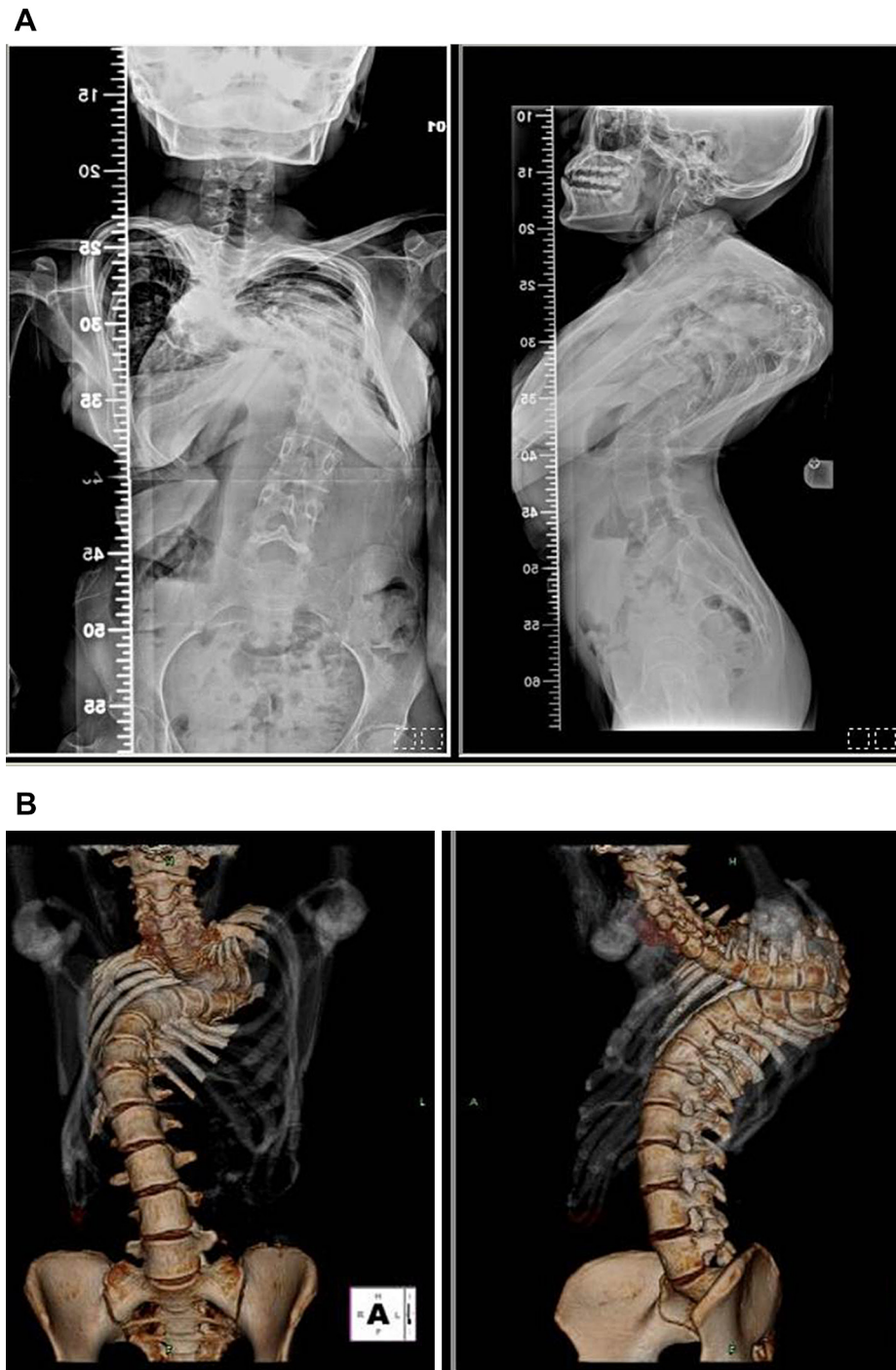


Fig. 1. A 16-year-old girl with kyphoscoliosis and Cobb angle greater than 100° . (A) Radiograph, anterior–posterior and lateral view. (B) Spinal 3D computed tomography reconstruction.

than 80° and vertebral body deformity (Fig. 1A) and B. A staged surgery was planned. In the first stage, we positioned all pedicle screws over T1–T3 and T7–T12. Subsequently, T4–T6 vertebral column resection, correction, and posteriolateral spinal fusion were performed (Fig. 2A and B). The purpose of the staged surgery was to reduce the duration of the complex operation, decrease operative blood loss, and diminish the risk of anesthesia. After the operation, the patient still had to use Taylor brace protection until fusion mass was formed.

The other patient was a 2-year-and-10-month-old boy who was diagnosed to have bacille Calmette–Guerin (BCG) spine by CT-guided biopsy. There was vertebral body destruction at T4 and T5 levels, with more than 80° of Gibbus deformity, which was measured on a T-spine plain film, and cold paraspinal abscess formation at T4–T6 (Fig. 3A to D). By means of an anteriolateral approach after thoracotomy, paraspinal abscess debridement, T4–T6 vertebral column resection with structure bone graft reconstruction, and vertical expandable prosthetic titanium rib application at right anteriolateral thoracic cage were performed (Fig. 4A and B). After the surgery, the patient had to use a body cast for 2 months because he had poor compliance with the back brace.

The two patients received our standard preoperative evaluation protocol including complete blood count and differential count (CBC/DC), electrolyte, liver function, renal function, cardiac sonography, bronchoscopy, and image study such as preoperative spinal plain film, whole spine MRI, and CT. There were no neurological deficits prior to and after the operation in both patients. The procedures were performed by the same surgeon at the orthopedic department of Taipei Veterans General Hospital. We also gave a

simple questionnaire to the patients' families for quality evaluation. With the aid of these full-scale spinal models, all surgical procedures were performed exactly according to the preoperative plan without any complications such as spinal cord or major neurovascular injury. The models were applied to identify the anatomic landmarks on the operating table in exposed spine segments. Prior to the insertion of pedicle screws, we not only consulted the 3D RP model for the severe deformity of the spine but also confirmed the trajectory of the pedicle screws through navigation.

For the two patients, all preoperative planning, implant selection, and imagination of vertebral body resection were done according to plain film, MRI, CT, 3D reconstruction CT, and the computer-designed real-size model. The manufacture of the RP model required certain procedures. First, the 3D spinal reconstruction was obtained on the basis of contiguous CT with a slice thickness of 1 mm. The scanning field involved the whole spine. Then, the digital imaging and communication in medicine (DICOM) format data of these two patients were downloaded. According to these data, the 3D reconstruction digital spine data were transferred to an STL format file by the software (Aquarius iNtution Edition version 4.4; TeraRecon, Inc., Headquarters, 2955 Campus Drive #325, San Mateo, CA 94403, USA) to produce the real-size model. Finally, we used a 3D printer of fused deposition modeling technology (Z510; Z Corporation, Boston, MA, USA) to build a computer-designed 3D model.

The manufacturing time—from the patient's agreement until the transformation of CT reconstruction files to the 3D RP model output—lasted about 7 days in this study. It cost less than NT\$20,000 to create a real-size model. Both models were exactly the same size as the actual deformity (Figs. 5 and 6), and they

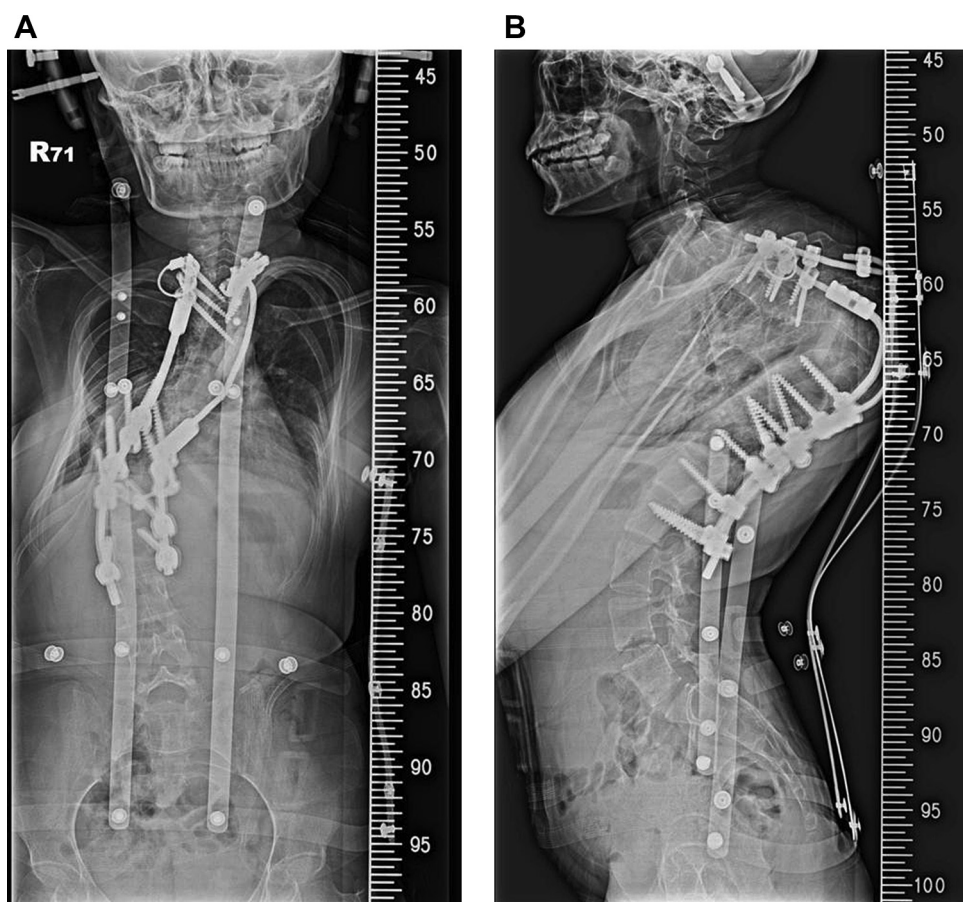


Fig. 2. Postoperative (final stage) radiography of the 16-year-old girl: (A) anterior–posterior view and (B) lateral view.

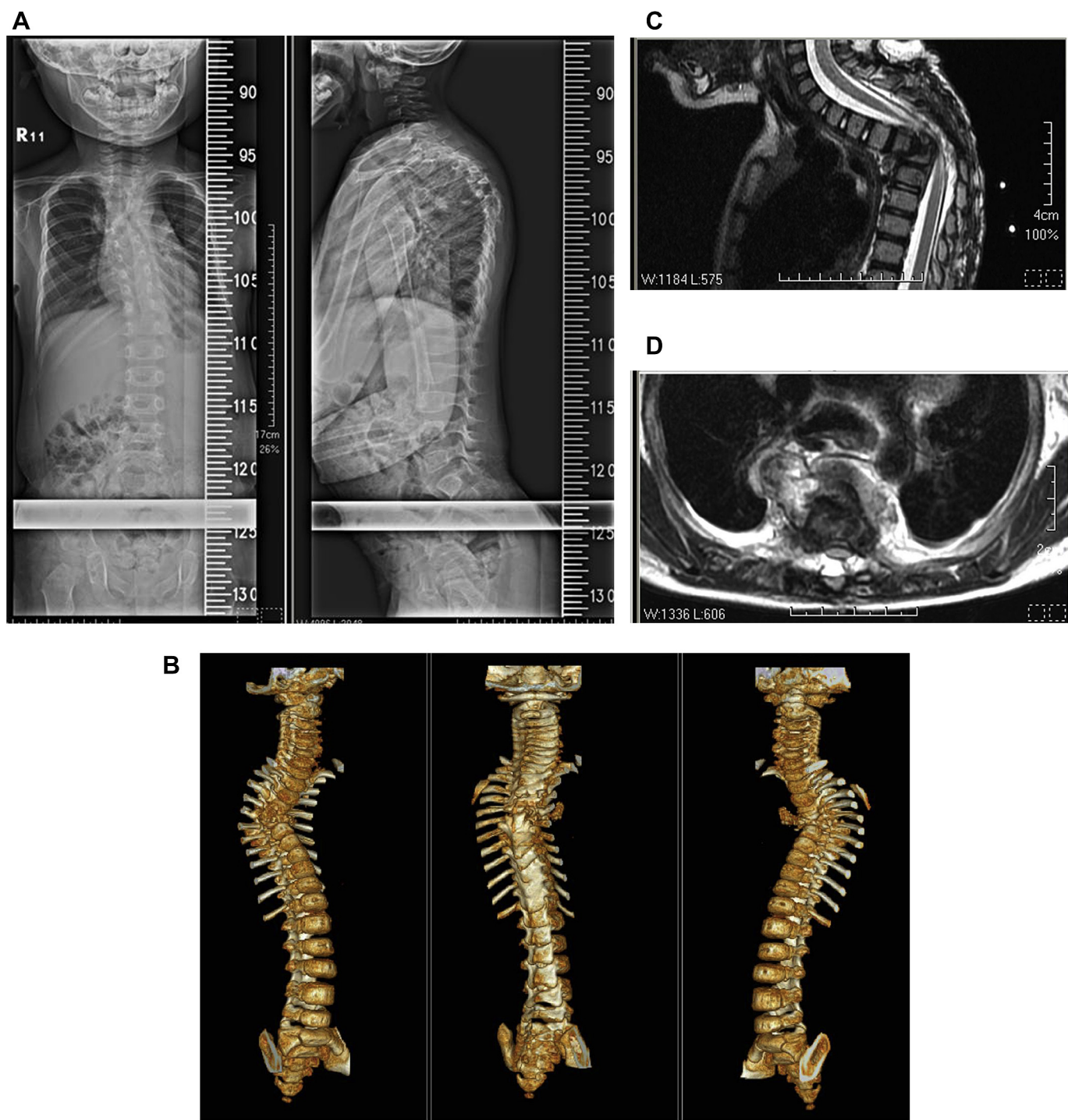


Fig. 3. A 2-year-and-10-month-old boy with BCG spine, T4–T6 paraspinous abscess formation and kyphotic deformity. (A) Radiograph, anterior–posterior and lateral views. (B) Spinal 3D computed tomography reconstruction. (C) T-spine magnetic resonance imaging (MRI) T₂-weighted sagittal view. (D) T-spine MRI T₂-weighted coronal view.

provided a tactile anatomic representation of the spinal deformity that allowed surgeons to plan the operation, simulate the operation process, choose the appropriate fixation instrumentation, and communicate with patients. During the surgery, these models were used on the operating table to identify the landmarks of the exposed spinal deformity. The result of the simple questionnaire given to each patient's family is shown in Table 1. The answers ranged from grade 5 (highly beneficial) to grade 0 (not beneficial at all).

3. Discussion

Prior to the treatment of any complex spinal deformity begins, an evaluation of overall deformities and preoperative plan is crucial. Although it is possible to comprehend the complex spinal pathology using current imaging methods, such as CT, 3D CT, or MRI, these 2D images can only provide limited morphometric information about the deformities due to vertebral rotation, scoliosis, kyphosis, or other factors.^{10,11} Moreover, the discovery of an

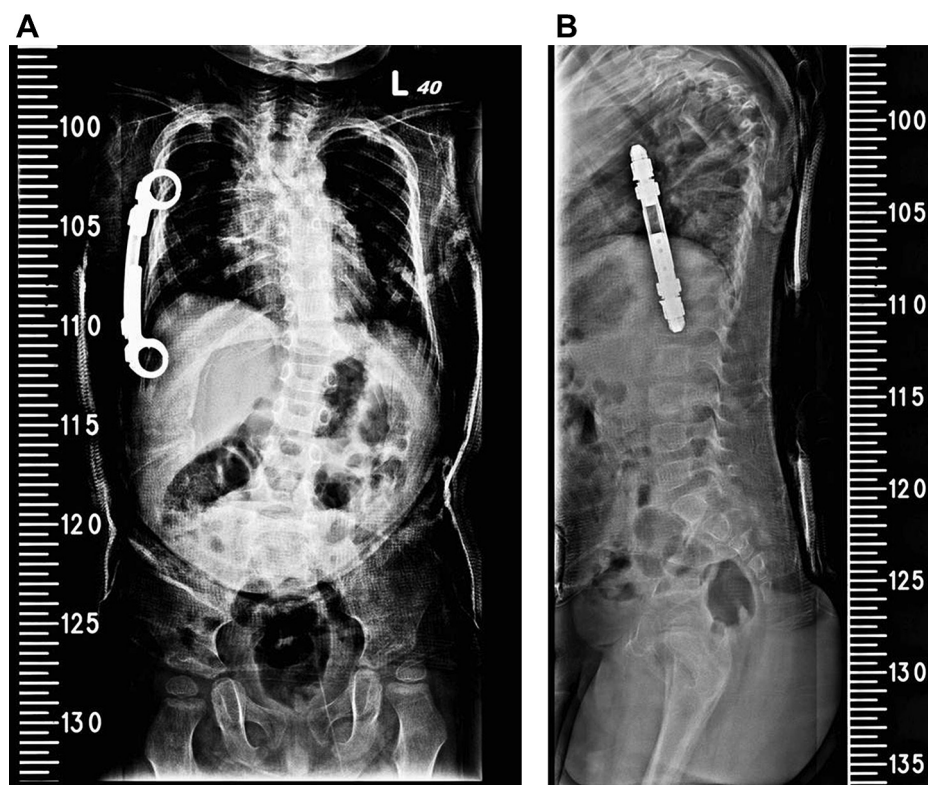


Fig. 4. Postoperative radiography of the 2-year-and-10-month-old boy: (A) anterior–posterior view and (B) lateral view.



Fig. 5. The rapid prototyping 3D model of the 16-year-old girl.

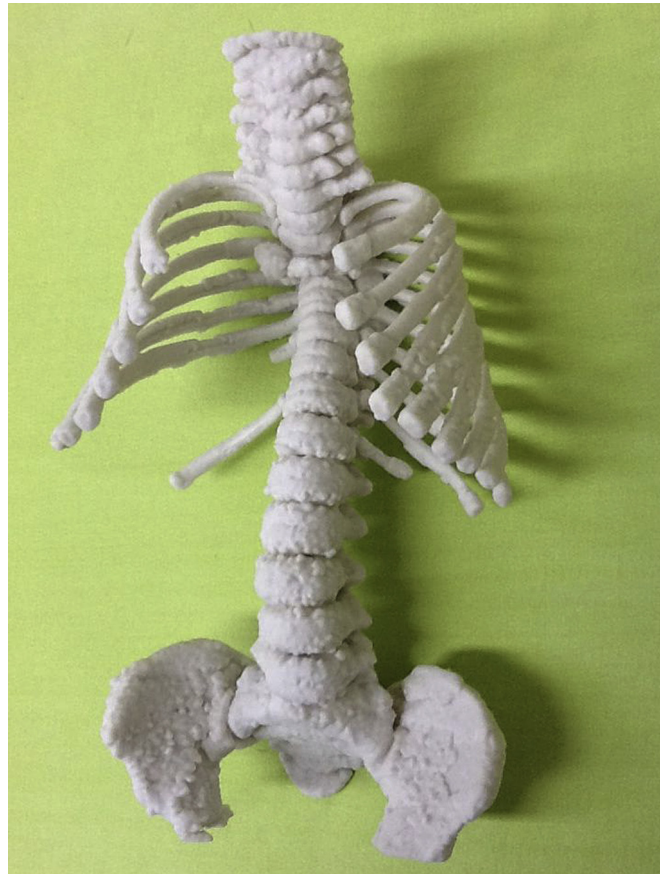

Fig. 6. The rapid prototyping 3D model of the 2-year-and-10-month-old boy.

Table 1

The questionnaires about the quality evaluation of RP model for patients and their family.

Questionnaire	Patient 1 (BCG spine)	Patient 2 (NF)
How beneficial for understanding of deformity	5	5
How beneficial for understanding of pre-OP plan	5	5
How beneficial for understanding of operative risk	5	5
Did the RP model affect your decision?	Yes	No
Was the cost of the RP model acceptable?	Expensive!	Yes

BCG = bacille Calmette-Guerin; NF = neurofibromatosis; RP = rapid prototyping.

unexpected deformity during the operation often complicates the procedure, increases the risk, and lengthens the duration of the surgery.⁹ 3D reconstruction CT can give surgeons the stereo and rotation of spinal deformities.³ A study showed the efficacy of 3D CT reconstruction in identifying congenital vertebral anomalies.¹² However, 3D CT reconstruction only shows the image of the spine on the screen, and not the full-scale spine.

As a tool for preoperative planning, the RP models can directly provide visual and tactile feedback and are most beneficial in terms of designing the surgical plan, anatomical representation, intra-surgical navigation, and communication with patients.^{7,8,13–15} Wu et al.¹⁶ reported 62 patients with congenital scoliosis of hemi-vertebra who were divided into two groups: the intraoperative fluoroscopy technique group and the RP technique group. The conclusion is that the application of the RP technique in congenital scoliosis can reduce the operation time and the risk of screw misplacement and its consequent complications. As far as we know, our two cases are the first to be reported in Taiwan for preoperative planning with the assistance of the RP model in the complex spinal surgery. In our experience, the RP model helped us to propose the preoperative plan and communicate with patients and their families. During the surgery, we could precisely perform the vertebral column resection and confirm the trajectory of instrumentation with the help of the 3D RP model. For patients and their families, the greatest benefit of the RP model was that it enabled them to realize the severity of the deformity and how the surgery would be performed. It is not easy for most patients without a medical background to understand the complex spinal deformity through CT, MRI, or 3D CT, which present as 2D images. Therefore, the real-size RP models give these patients the tactile and visual information about the deformity.

Nevertheless, we still encountered several difficulties. First, it took about 7 days to prepare the RP model. Yet with further improvements, the RP model could have been produced in less than 48 hours.¹⁷ The problem was the lack of an automatic file transformation program. If we want to apply the technology to trauma cases, this problem must be solved, and the prototyping process has to be accomplished within 24 hours. Second, the texture of the RP models did not reflect real bone material and thus failed to present osteoporosis or spinal flexibility. Therefore, we were not able to stimulate the outcome after correcting the deformity. Finally, the RP model could not show the condition of the surrounding soft tissue such as the adhesion between dura and spine or the different

track of nerve roots in the complex spinal deformity. In the future, if the fusion of CT and MRI images becomes possible, we will be able to improve the RP technique to make the spinal cord, nerve root, and bony structure visible at the same time.

In conclusion, this study has shown that, compared to spinal plain film, CT, MRI, or 3D CT reconstruction, the 3D RP models are more helpful in directly providing visual and tactile feedback, improving preoperative planning, identifying the important anatomic landmarks during the surgery, and communicating with patients. If the RP technique can be improved with respect to, for instance, reduction of prototyping time and cost, the use of 3D RP models will become more acceptable and practical in Taiwan.

References

- D.J. Hedequist. Surgical treatment of congenital scoliosis. *Orthop. Clin. North Am.* 38 (2007) 497–509 vi.
- A. Hamzaoglu, C. Ozturk, M. Tezer, M. Aydogan, M. Sarier, U. Talu. Simultaneous surgical treatment in congenital scoliosis and/or kyphosis associated with intraspinal abnormalities. *Spine (Phila Pa 1976)* 32 (2007) 2880–2884.
- L. Bonnier, K. Ayadi, A. Vasdev, G. Crouzet, B. Raphael. Three-dimensional reconstruction in routine computerized tomography of the skull and spine. Experience based on 161 cases. *J. Neuroradiol* 18 (1991) 250–266.
- S.T. Woolson, P. Dev, L.L. Fellingham, A. Vassiliadis. Three-dimensional imaging of bone from computerized tomography. *Clin. Orthop. Relat. Res* 202 (1986) 239–248.
- T.M. Barker, W.J. Earwaker, N. Frost, G. Wakeley. Integration of 3-D medical imaging and rapid prototyping to create stereolithographic models. *Australas. Phys. Eng. Sci. Med* 16 (1993) 79–85.
- P.S. D'Urso, G. Askin, J.S. Earwaker, G.S. Merry, R.G. Thompson, T.M. Barker, D.J. Effeney. Spinal biomodeling. *Spine (Phila Pa 1976)* 24 (1999) 1247–1251.
- M. van Dijk, T.H. Smit, T.U. Jiya, P.I. Wuisman. Polyurethane real-size models used in planning complex spinal surgery. *Spine (Phila Pa 1976)* 26 (2001) 1920–1926.
- J. Guarino, S. Tennyson, G. McCain, L. Bond, K. Shea, H. King. Rapid prototyping technology for surgeries of the pediatric spine and pelvis: benefits analysis. *J. Pediatr. Orthop* 27 (2007) 955–960.
- K. Mao, Y. Wang, S. Xiao, Z. Liu, Y. Zhang, X. Zhang, Z. Wang, et al. Clinical application of computer-designed polystyrene models in complex severe spinal deformities: a pilot study. *Eur. Spine J* 19 (2010) 797–802.
- U.R. Liljenqvist, T. Allkemper, L. Hackenberg, T.M. Link, J. Steinbeck, H.F. Halm. Analysis of vertebral morphology in idiopathic scoliosis with use of magnetic resonance imaging and multiplanar reconstruction. *J. Bone Joint Surg. Am.* 84-A (2002) 359–368.
- F.A. Facanha-Filho, R.B. Winter, J.E. Lonstein, S. Koop, T. Novacheck, E.A. L'Heureux Jr., C.A. Noren. Measurement accuracy in congenital scoliosis. *J. Bone Joint Surg. Am.* 83-A (2001) 42–45.
- D.J. Hedequist, J.B. Emans. The correlation of preoperative three-dimensional computed tomography reconstructions with operative findings in congenital scoliosis. *Spine (Phila Pa 1976)* 28 (2003) 2531–2534 discussion 1.
- J.C. Yang, X.Y. Ma, J. Lin, Z.H. Wu, K. Zhang, Q.S. Yin. Personalised modified osteotomy using computer-aided design-rapid prototyping to correct thoracic deformities. *Int. Orthop* 35 (2011) 1827–1832.
- V. Bagaria, S. Deshpande, D.D. Rasalkar, A. Kuthe, B.K. Paunipagar. Use of rapid prototyping and three-dimensional reconstruction modeling in the management of complex fractures. *Eur. J. Radiol* 80 (2011) 814–820.
- M.T. Izatt, P.L. Thorpe, R.G. Thompson, P.S. D'Urso, C.J. Adam, J.W. Earwaker, R.D. Labrom, et al. The use of physical biomodelling in complex spinal surgery. *Eur. Spine J* 16 (2007) 1507–1518.
- Z.X. Wu, L.Y. Huang, H.X. Sang, Z.S. Ma, S.Y. Wan, G. Cui, W. Lei. Accuracy and safety assessment of pedicle screw placement using the rapid prototyping technique in severe congenital scoliosis. *J. Spinal Disord. Tech* 24 (2011) 444–450.
- E. Debarre, P. Hivart, D. Baranski, P. Deprez. Speedy skeletal prototype production to help diagnosis in orthopaedic and trauma surgery. Methodology and examples of clinical applications. *Orthop. Traumatol. Surg. Res.* 98 (2012) 597–602.