

Case Report

Pedicule screw breakage in a vertebral body: A rare complication in a dynamic stabilization device

Yen-Chun Chiu, Shih-Chieh Yang*, Shang-Won Yu, Yuan-Kun Tu

Department of Orthopedic Surgery, E-Da Hospital/I-Shou University, Kaohsiung County, Taiwan, ROC

ARTICLE INFO

Article history:

Received 6 May 2011

Received in revised form

4 July 2011

Accepted 15 August 2011

Available online 22 October 2011

Keywords:

complication

dynamic stabilization device

pedicle screw breakage

complication

ABSTRACT

The Dynesys system is a nonfusion pedicle-screw stabilization system, an implant device designed to preserve intersegmental kinematics and reduce loading at facet joints. Several biomechanical in vitro experiments and clinical studies have proven the efficacy of the Dynesys. The most common complication associated with the use of this system is loosening of the pedicle screw. We present here a case of a patient who developed the rare complication of pedicle screw breakage following Dynesys instrumentation. Seven months after surgery, the patient experienced progressive, intractable back pain radiating to both the buttocks. Radiography revealed breakage of the left L5 pedicle screw in addition to a halo sign around the right pedicle screw. Revision surgery with a new Dynesys instrumentation and autologous bone graft was used to treat this complication.

Copyright © 2011, Taiwan Orthopaedic Association. Published by Elsevier Taiwan LLC. All rights reserved.

1. Introduction

Pedicule screw instrumentation is frequently used for spinal fixation, correction, reconstruction, and associated decompression in spinal trauma, degenerative disease, and related spinal disorders. This method has been shown to be more effective than spinal fusion without instrumentation or conservative treatment.^{1–3} However, a major concern is the potential for accelerated disc degeneration above or below a fused segment, a condition known as adjacent segment disease.^{4,5} Therefore, it is preferable to avoid or at least delay a fusion procedure in younger patients. An attractive alternative is a dynamic nonfusion system, which aims to maintain the mobility of the motion segment while preventing negative effects at the adjacent segments. Among the dynamic neutralization systems, the Dynesys (dynamic neutralization system for the spine; Zimmer GmbH, Winterthur, Switzerland) is arguably the most popular. A multicenter study proved that Dynesys is a safe and effective system for stabilizing the lumbar spine.^{6–8} The following case report documents a rare complication of pedicle screw breakage inside the vertebral body following use of Dynesys instrumentation for the management of lumbar degenerative disc disease with stenosis Fig. 1.

2. Case report

The patient was a 50-year-old fisherman who denied any prior systemic disease. He was hospitalized at a community hospital for disabling back pain radiating to both the legs and intermittent claudication for several months; the pain had been unrelieved by conservative treatment. On the basis of a diagnosis of L3–5 degenerative disc disease and associated stenosis, we performed L3–5 posterior decompression with Dynesys instrumentation. The surgery went smoothly and the patient was discharged from the hospital uneventfully Fig. 1. However, 3 months after surgery the patient experienced low back pain and right leg numbness. Radiography revealed loosening of the L5 pedicle screw on the right side. He was asked to take a pain-killer, and this enabled him to tolerate the symptoms. However, he started experiencing progressive intractable back pain radiating to both the buttocks 7 months after surgery. The symptom also worsened on the left side. Because the pain was too severe and interfered with his daily activity, he returned to our hospital seeking medical help. Radiography revealed breakage of the left L5 pedicle screw in addition to a halo sign around the right pedicle screw. Magnetic resonance imaging (MRI) studies of the lumbosacral spine revealed no other pathological lesion. The patient was admitted to our hospital for further management Fig. 2.

We conducted a detailed discussion with the patient regarding possible treatment modalities. He refused to undergo instrumented fusion surgery and insisted on using the dynamic device. Therefore,

* Corresponding author. Department of Orthopedic Surgery, E-Da Hospital/I-Shou University, 1 E-Da Road, Jiau-Shu Tsuen, Yan-Chau Shiang, 824 Kaohsiung County, Taiwan, ROC. Tel: +886 7 615 0011 2971; fax: +886 7 615 5352.

E-mail address: skyspine@gmail.com (S.-C. Yang).

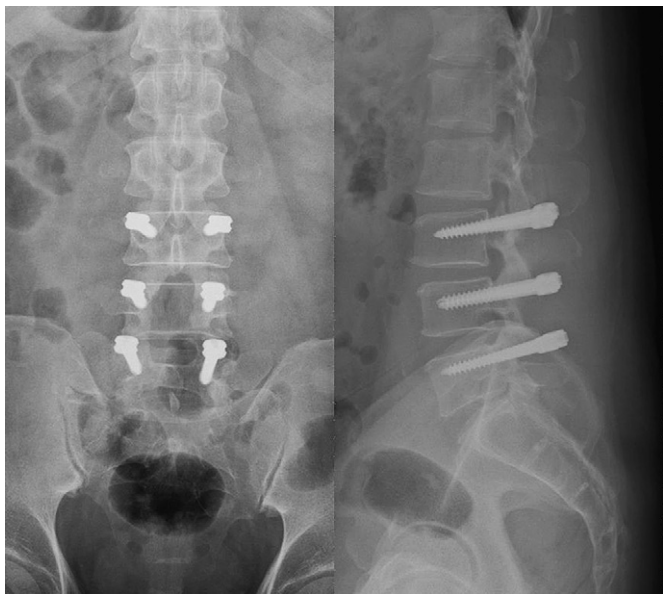


Fig. 1. A 50-year-old man diagnosed with L3–5 degenerative disc disease and associated stenosis underwent L3–5 posterior decompression with Dynesys instrumentation. Postoperative radiography showed good alignment and positioning of pedicle screws.

an alternative strategy with unpredictable results was carefully discussed with the patient and his family before he underwent surgery. Using a posterior approach through the previous operative wound that extended deep into the Dynesys, the proximal part of the broken left L5 pedicle screw was removed and the screw hole was impacted using posterior autologous iliac bone graft. Subsequently, a new Dynesys pedicle screw was inserted through the pedicle into the L5 vertebral body in a different direction. The right L5 pedicle screw was also removed, and the screw hole was augmented using autologous bone graft to ensure the fixation and stability of the reimplanted right L5 pedicle screw *Fig. 3*.

The intractable back pain and associated sciatica improved substantially after surgery. The patient was advised to wear



Fig. 3. The broken pedicle screw removed from the left L5 pedicle.

a Taylor's brace for short-term protection. He was discharged from the hospital on the 5th postoperative day. No recurrent complication was observed during the 2-year postoperative follow-up *Fig. 4*.

3. Discussion

Pedicle screw fixation is indicated for the management of numerous spinal disorders and deformities. It offers the advantages of immediate stabilization, higher rates of spinal fusion, and easy contouring. However, the complications associated with the use of pedicle screws have been encountered and reviewed in several studies.^{9–11} One of the most common complications mentioned in these reports is screw breakage, which occurs in 1–11.2% of inserted screws and in 0.4–24.5% of treated patients. An instrumented posterior fusion procedure resulting in pseudarthrosis can lead to pedicle screw or rod breakage. With any instrumented fusion, it is a race between failure of the instrumentation and healing of the fusion procedure.¹²

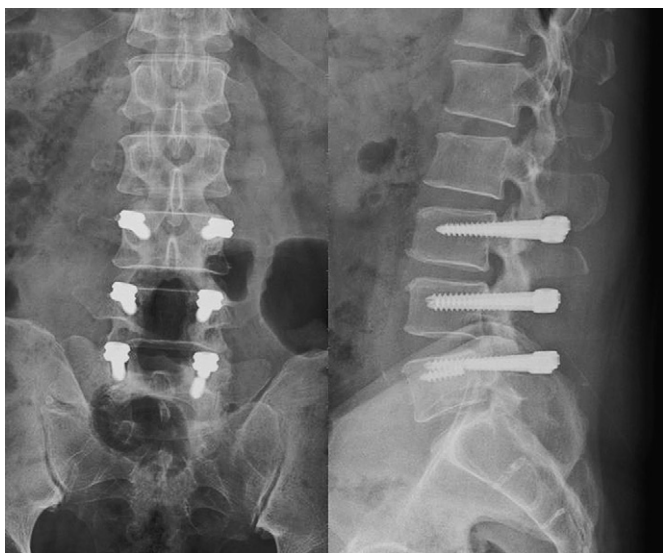

Fig. 2. The patient complained of progressive intractable low back pain 7 months after surgery. Repeat radiography revealed loosening of the right L5 pedicle screw and breakage of the left L5 pedicle screw.

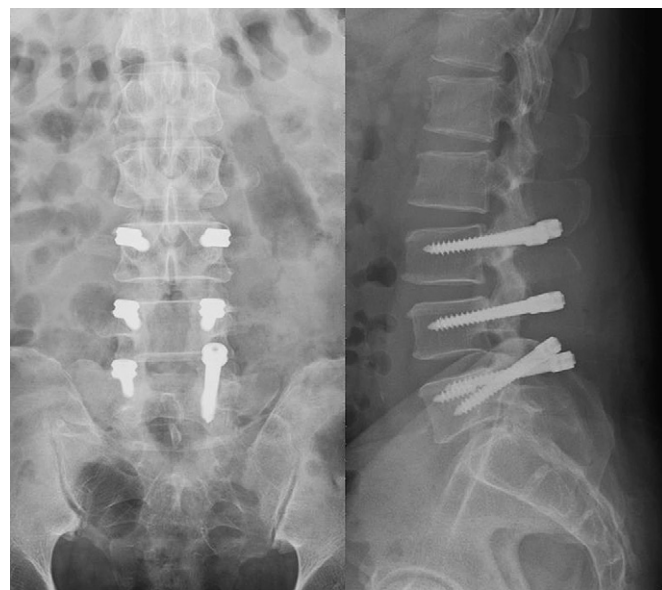


Fig. 4. The patient underwent revision surgery with Dynesys. Radiography 12 months after surgery showed reimplantation of the left L5 pedicle screw and augmentation of both L5 pedicle screw holes using autologous bone graft.

An alternative to fusion is dynamic posterior stabilization that can be used for treating degenerative problems of the lumbar spine. The Dynesys is one such device that has been designed to preserve intersegmental kinematics and reduce loading at facet joints. Several biomechanical *in vitro* experiments and clinical studies have proven the efficacy of the Dynesys. However, the most common complication associated with the use of this system is the loosening of the pedicle screw.^{6–8,13–16} Our case appears to be a rare complication of a patient developing pedicle screw breakage following Dynesys instrumentation.

In 1982, Kirkaldy-Willis and Farfan¹⁷ presented a convincing concept of degeneration to describe the pathogenesis of spinal instability in degenerative spondylosis. Spinal instability includes three phases: dysfunction, instability, and restabilization of the motion segment. In the dysfunction phase, the disc undergoes nuclear dehydration and annular weakening with the development of protrusions and tears, and loses its resistance to rotational and translational forces. Subsequently, degeneration of the facet joints occurs, along with cartilage destruction and deformation to a more sagittal alignment. In the third phase, the stability is regained by disc collapse, spondylophyte formation, osteochondrosis, and locking of the facets. Spinal instrumentation is generally targeted towards managing some form of instability.

The Dynesys is a non-fusion pedicle screw-based stabilization system. It was introduced in 1994 by Dubois and colleagues, on the basis of the hypothesis that, using this implant, segmental stabilization could be achieved without bone grafting.⁶ Dynesys consists of three components: (1) titanium alloy pedicle screws that have a textured surface, fixed head, and self-tapping threads; (2) tensioning cords made of polyethylene terephthalate; and (3) longitudinal tubular spacers made of polycarbonate urethane. The screws anchor the Dynesys in the pedicle and in the vertebral body. The spacers fit between the pedicle screw heads, and the stabilization cords connect the pedicle screw heads via the hollow core of the spacer and hold the spacer in place. The preload provides uniform system rigidity, the stabilizing cords carry tensile forces, and the spacers resist compressive forces. This system establishes a mobile load transfer and controls motion of the segment in all planes. Compared to the sole decompression of an unstable segment or the fusion of such a segment, controlled segmental motion enhances stability, and helps achieve a more physiological condition. In a biomechanical study, Schmoelz et al¹³ found that the Dynesys was more flexible than traditional pedicle screw fixation in all three primary loading directions, but in general, was substantially stiffer than the intact spine.

The Dynesys is designed to treat the later stages of the first phase and the second phase of spinal instability. Other indications for the Dynesys are mono- or multi-segmental degenerative disc disease that causes low back pain, iatrogenic instability following decompression, and stenosis with early stages of gradually developing degenerative scoliosis. In multilevel degenerative disc disease, the Dynesys may also be combined with a fusion procedure.^{6–8}

Approximately 8 months post-surgery, the patient described in this report experienced L5 right pedicle screw loosening and left pedicle screw breakage. Pedicle screw loosening is commonly reported in this type of dynamic device because of its flexibility and load-transfer characteristics. The overall rate of complications was low in the literature. In a consecutive series of 94 patients undergoing treatment with Dynesys, Bordes-Monmeneu et al¹⁸ reported only one case with screw misplacement, one broken screw, and two patients presenting with a late infection. Wurgler-Hauri et al¹⁹ demonstrated a higher rate of material failure in terms of broken screws (1.8%) and loose systems which needed to be replaced. In

a multicenter study, Stoll et al⁷ reported nine complications all unrelated to the implant, and one resulting from screw misplacement. However, these articles did not especially address or discuss the issue of broken screws. It is difficult to explain implant fracture, particularly when the implant is located in an intravertebral position. Possible mechanisms include product defects, iatrogenic or technical problems during operation (malposition or malorientation of the pedicle screw), vertebral osteosclerosis resulting in a stress riser within the screw, major or minor trauma with unusual loading, and fatigue failure of the screw because of overloading or high levels of daily activity. Moreover, there is always the possibility of implant failure or breakage following pedicle screw implantation. It should be kept in mind that various types of spinal surgeries are associated with specific complications. A thorough knowledge of the implanted product, detailed surgical procedures, and possible complications, as well as meticulous surgical technique, can help avoid undesired complications. If these complications occur, prompt recognition and adequate salvage procedures are mandatory to minimize long-term sequelae.

Most spinal surgeons would agree that instrumented spinal fusion using bone grafting is a standardized salvage method to treat this patient. However, revision with Dynesys is an acceptable alternative treatment choice. The location and orientation of the reimplanted pedicle screw and the spacer surrounding the tensioned cord between the neighboring screws is modified in the revision surgery; this would certainly influence the survival of the Dynesys and the clinical outcome of the patient. Niosi et al²⁰ investigated the biomechanical characterization of the three-dimensional kinematic behaviour of the Dynesys. They concluded that spacer length had a significant effect on the range of motion. A longer spacer resulted in a range of motion and pattern of motion that was close to that seen in an intact specimen. However, the few posterior dynamic stabilization systems that have thus far been used in the clinical setting have produced clinical outcomes comparable with those produced by fusion.

In conclusion, we present the case of a patient who experienced pedicle screw breakage following the use of Dynesys instrumentation. A dynamic stabilization device must provide stability throughout its lifetime, unless it allows for reparative processes that can reverse the degenerative changes. Anchorage of the implant into bone is crucial, at least for a transpedicular system. Although the use of nonfusion stabilization devices could provide several advantages compared with fusion, the possibility of severe adverse events such as pedicle breakage must be considered. The use of established surgical techniques, a comprehensive understanding of the dynamic stabilization system, and careful selection of suitable patients can help prevent these undesired complications.

References

1. R.W. Gaines Jr. The use of pedicle-screw internal fixation for the operative treatment of spinal disorders. *J Bone Joint Surg Am* 82 (2000) 1458–1476.
2. R. Masferrer, C.H. Gomez, D.G. Karahalios, V.K. Sonntag. Efficacy of pedicle screw fixation in the treatment of spinal instability and failed back surgery: a 5-year review. *J Neurosurg* 89 (1998) 371–377.
3. C.H. Wu, Y.H. Kao, S.C. Yang, T.S. Fu, P.L. Lai, W.J. Chen. Supplementary pedicle screw fixation in spinal fusion for degenerative spondylolisthesis in patients aged 65 and over: outcome after a minimum of 2 years follow-up in 82 patients. *Acta Orthop* 79 (2008) 67–73.
4. P. Park, H.J. Garton, V.C. Gala, J.T. Hoff, J.E. McGillicuddy. Adjacent segment disease after lumbar or lumbosacral fusion: review of the literature. *Spine* 29 (2004) 1938–1944.
5. W.J. Chen, P.L. Lai, C.C. Niu, L.H. Chen, T.S. Fu, C.B. Wong. Surgical treatment of adjacent instability after lumbar spine fusion. *Spine* 26 (2001) E519–E524.
6. O. Schwarzenbach, U. Berlemann, T.M. Stoll, G. Dubois. Posterior dynamic stabilization systems: Dynesys. *Orthop Clin N Am* 36 (2005) 363–372.
7. T.M. Stoll, G. Dubois, O. Schwarzenbach. The dynamic neutralization system for the spine: a multi-center study of a novel non-fusion system. *Eur Spine J* 11 (2002) S170–S178.

8. K.J. Schnake, S. Schaeren, B. Jeanneret. Dynamic stabilization in addition to decompression for lumbar spinal stenosis with degenerative spondylolisthesis. *Spine* 31 (2006) 442–449.
9. P.C. McAfee, D.J. Weiland, J.J. Carlow. Survivorship analysis of pedicle spinal instrumentation. *Spine* 16 (1991) S422–S427.
10. H. Pihlajamäki, P. Myllynen, O. Bostman. Complications of transpedicular lumbosacral fixation for non-traumatic disorders. *J Bone Joint Surg Br* 79 (1997) 183–189.
11. C.A. Brown, F.J. Eismont. Complications in spinal fusion. *Orthop Clin N Am* 29 (1998) 679–699.
12. J.E. Lonstein, F. Denis, J.H. Perra, M.R. Pinto, M.D. Smith, R.B. Winter. Complications associated with pedicle screws. *J Bone Joint Surg Am* 81 (1999) 1519–1528.
13. W. Schmoelz, J.F. Huber, T. Nydegger, Claes L. Dipl.-Ing, H.J. Wilke. Dynamic stabilization of the lumbar spine and its effects on adjacent segments: an in vitro experiment. *J Spinal Disord Tech* 16 (2003) 418–423.
14. H.J. Wilke, F. Heuer, H. Schmidt. Prospective design delineation and subsequent in vitro evaluation of a new posterior dynamic stabilization system. *Spine* 34 (2009) 255–261.
15. C.A. Niosi, D.C. Wilson, Q. Zhu, O. Keynan, D.R. Wilson, T.R. Oxland. The effect of dynamic posterior stabilization on facet joint contact forces: an in vitro investigation. *Spine* 33 (2008) 19–26.
16. B.W. Cunningham, J.M. Dawson, N. Hu, S.W. Kim, P.C. McAfee, S.L. Griffith. Preclinical evaluation of the Dynesys posterior spinal stabilization system: a nonhuman primate model. *Spine J* 10 (2010) 775–783.
17. W.H. Kirkaldy-Willis, H.F. Farfan. Instability of the lumbar spine. *Clin Orthop* 165 (1982) 110–123.
18. M. Bordes-Monmeneu, V. Bordes-Garcia, F. Rodrigo-Baeza. System of dynamic neutralization in the lumbar spine: experience on 94 cases. *Neurocirugia* 16 (2005) 499–506.
19. C.C. Wurgler-Hauri, A. Kalbarczyk, M. Wiesli, H. Landolt, J. Fandino. Dynamic neutralization of the lumbar spine after microsurgical decompression in acquired lumbar spinal stenosis and segmental instability. *Spine* 33 (2008) E66–E72.
20. C.A. Niosi, Q.A. Zhu, D.C. Wilson, O. Keynan, D.R. Wilson, T.R. Oxland. Biomechanical characterization of the three-dimensional kinematic behaviour of the Dynesys dynamic stabilization system: an in vitro study. *Eur Spine J* 15 (2006) 913–922.